A Thoraco-Lumbo-Sacral Orthosis for Idiopathic Scoliosis

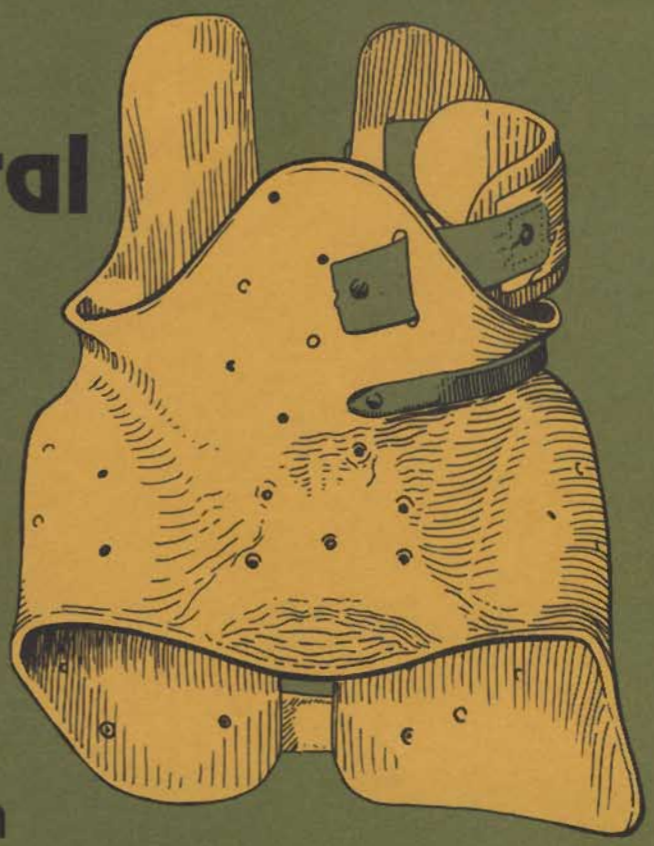

by J. Martin Carlson

Gillette Children's Hospital

The "Gillette" style Thoraco-Lumbo-Sacral orthosis is an orthotic design for the treatment of certain spine deformities in skeletally immature patients. Like several other contemporary designs, it avoids the use of a neck ring. However, this design leaves a major portion of the trunk uncovered and unconstrained allowing the patient a great deal of freedom of motion.

In this manual, we will be discussing: the indications and contraindications for this orthosis...the design of the orthosis and...the mechanics of the orthosis. A second manual covering the details of providing the orthosis will soon be available.

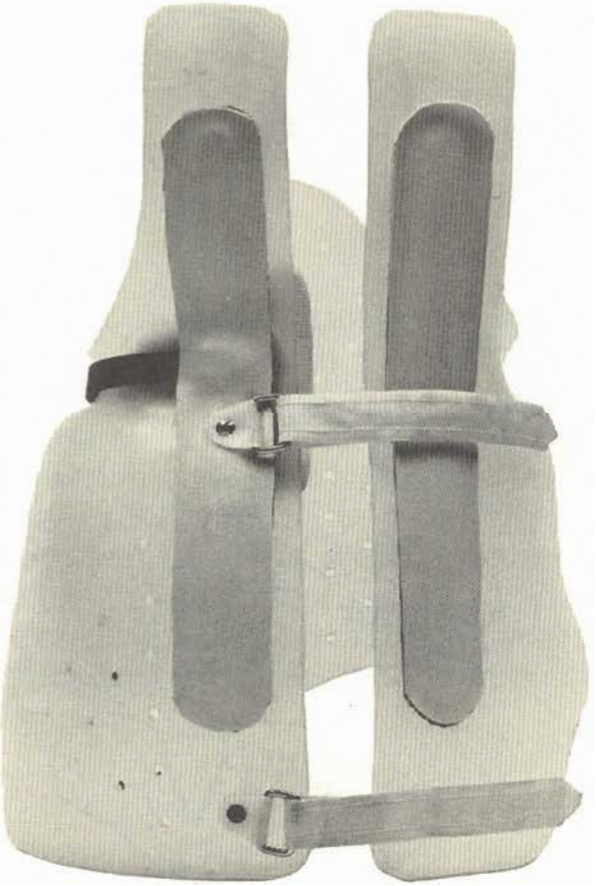

INDICATIONS and CONTRAINDICATIONS

Indications for the "Gillette TLSO" are, of course, very similar to the indications for a "Milwaukee CTLSO". There are some differences, however. We advocate the use of this orthosis for the treatment of scoliotic curves whose apical or horizontal vertebra is not higher than "T_{12}" (figure 1). Application of a "TLSO", which reduces lumbar lordosis, almost invariably causes a reduction in thoracic roundness. For this reason, we do not advocate the use of this orthosis on patients with a thoracic kyphosis of less than fifteen degrees (figure 2). We feel these situations are better treated with a Milwaukee CTLS-Orthosis.

Figure 2

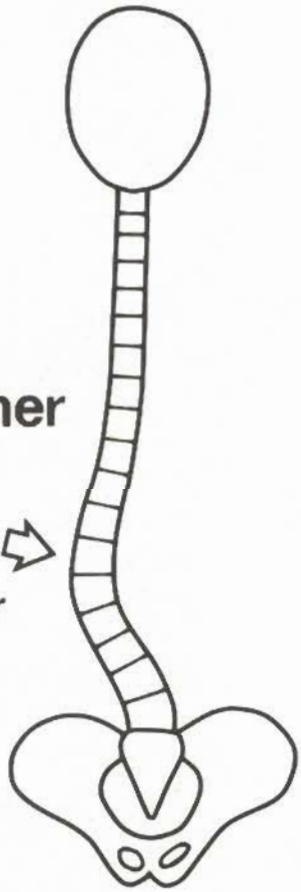

Figure 1

The TLS-Orthosis has also been used successfully for spine deformities in the sagittal plane. It is very effective in reducing excessive lumbar lordosis. It should be *used only very selectively for treatment of* excessive thoracic kyphosis. We advocate the Gillette TLS-Orthosis for treatment of excessive thoracic kyphosis only when all of the following criteria are met:

One, the apex of the kyphosis is not higher than "T_9".

Two, the kyphosis measures less than sixty degrees.

Three, the kyphosis demonstrates good flexibility. In other words, it can be

extended to a kyphotic angle of less than 40 degrees.

Four, the patient exhibits a lumbar lordosis of greater than fifty-five degrees.

Before leaving the topic of indications, we should stress that passive control of the upper thorax and neck position is absent. We are relying to some extent on the patient's desire and ability to line up his shoulders and head in a proper relationship to his lower torso and in proper relationship to the horizon (figure 3). This

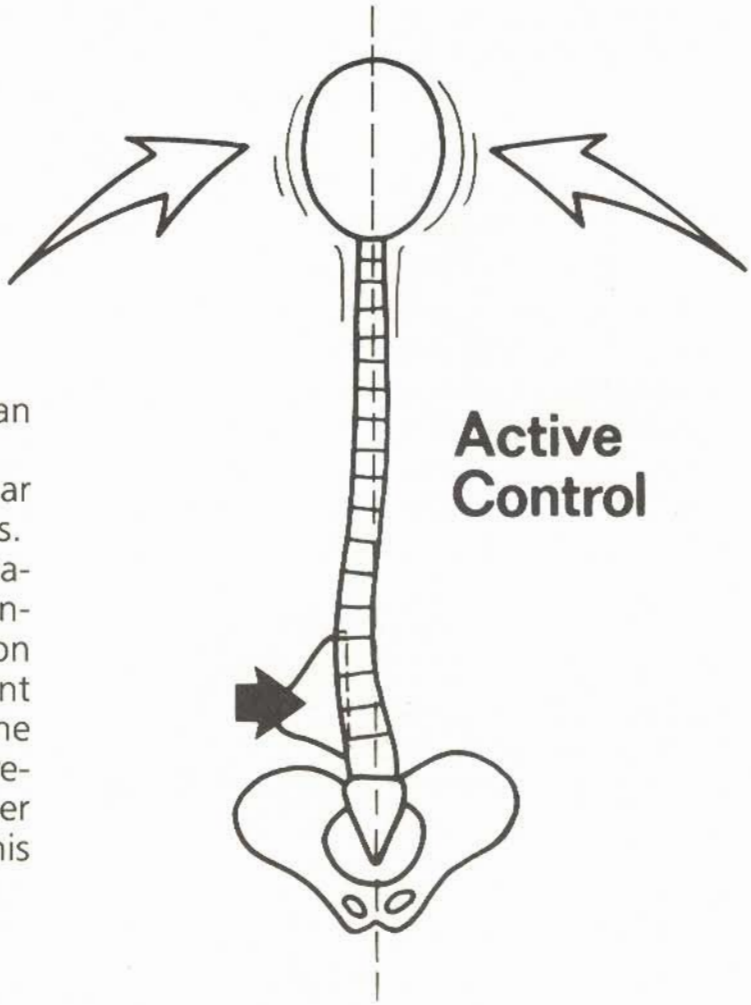

Figure 3

orthosis is, therefore, usually not appropriate for patients with neuromuscular diseases.

To simplify our discussion of design and mechanics, we will be relating these things exclusively to left lumbar or thoraco-lumbar curves. We have chosen to relate to left lumbar curves because the disease exhibits such a strong pattern of producing left curves in this region of the spine.

DESIGN

The design of the "Gillette" style Thoraco-Lumbo-Sacral Orthosis contains many features and concepts which are not new. The TLS-Orthosis in many respects resembles the pelvic section of a Milwaukee Orthosis. This is certainly no accident; and just as we have learned from Doctors Blount and Schmidt, the designers of the Milwaukee Orthosis, we have learned from others. We avoid claims to total originality.

Each orthosis is custom fabricated over a positive model of the patient. The model, of course, possesses the size and contours of the individual patient. However, the asymmetrical deformities due to lumbar or thoraco-lumbar scoliosis are reversed on the positive before vacuum forming the basic plastic shell. Polypropylene is utilized for the shell, and stainless steel is used for the reinforcement bars.

Lumbar pressure is exerted by means of a lumbar pad (figure 4). The lumbar pad is fabricated of firm polyethylene foam. Its position and thickness can be easily varied by the orthotist because velcro is utilized to fasten it in position inside the orthosis.

For thoraco-lumbar scoliosis, a low thoracic pad is also used (figure 5). It is fabricated of one millimeter thick

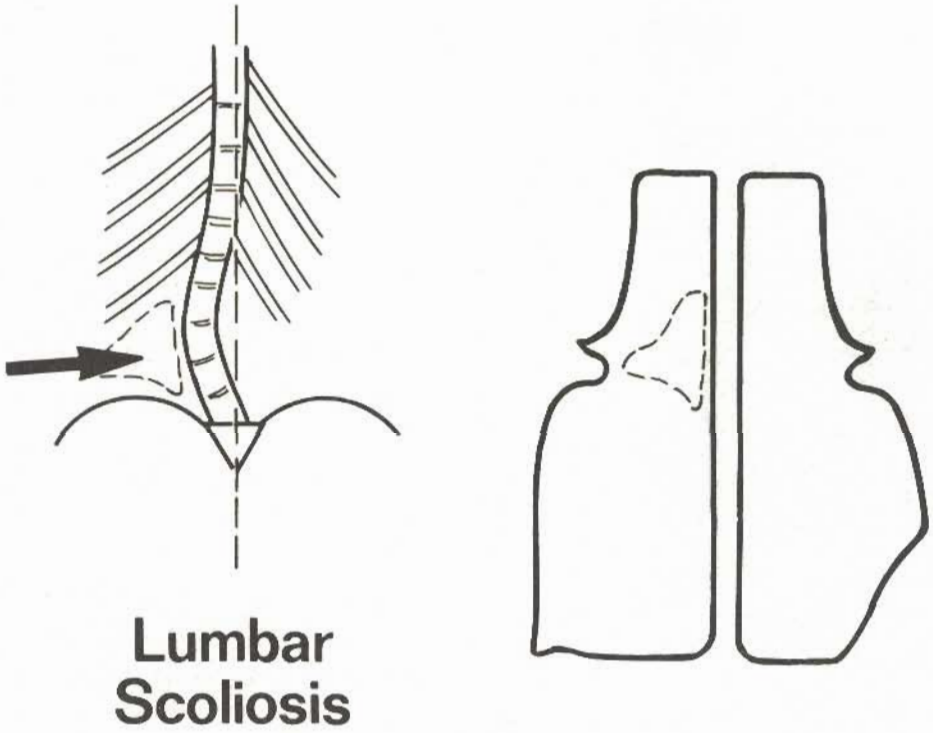

Figure 4

Figure 5

Thoraco-Lumbar Scoliosis

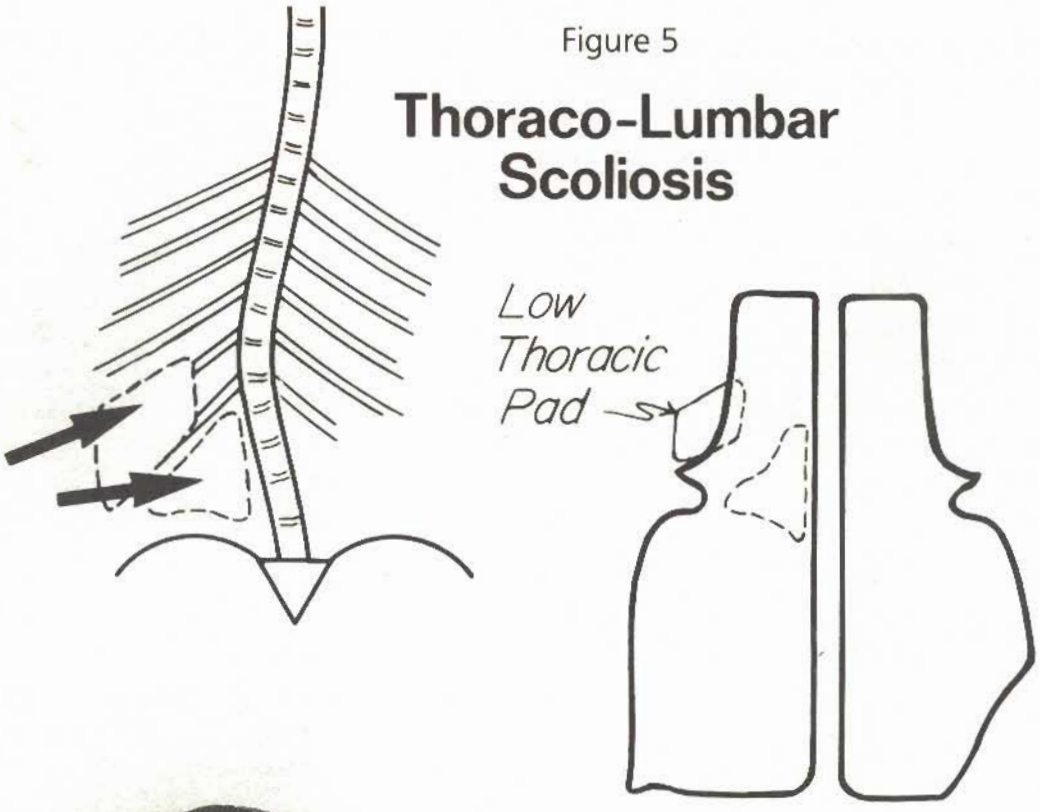

Figure 6

polyethylene faced with six millimeter "Plastazote" padding. It is flexible enough to follow the exact contour of the thorax. It is slung in place in the fashion of the Milwaukee Orthosis (figure 6). Like the Milwaukee thoracic pad, it can easily be adjusted as to position and pressure.

Lead foil strips are built into all pads so that their placement can be precisely and easily checked on the X-ray.

The trim lines of the orthosis anteriorly are equivalent to those of a Milwaukee Orthosis pelvic section. Posteriorly and laterally, they differ considerably. Two posterior thoracic extensions are created para-spinally and terminate two centimeters inferior to the scapulae. These extensions are about seven centimeters wide. The lateral border sweeps almost straight downward to blend with the usual lateral trim line above the waist. On the same side as the lumbar pad, a trochanteric extension is created by continuing the inferior-

posterior border straight around laterally past mid-line and then sharply upward to blend with the rectus femoris relief. On the opposite side, the trim line sweeps upward to blend with the rectus femoris relief along a line passing superior to the greater trochanter.

Reinforcement is provided by two metal reinforcement bars para-spinally and by a semi-circumferential bar in the waist groove on the same side as the lumbar pad (figure 7).

As you can see, this orthosis leaves a major portion of the trunk uncovered and unconstrained, allowing a great deal of openness, torso motion, and exercise in the orthosis.

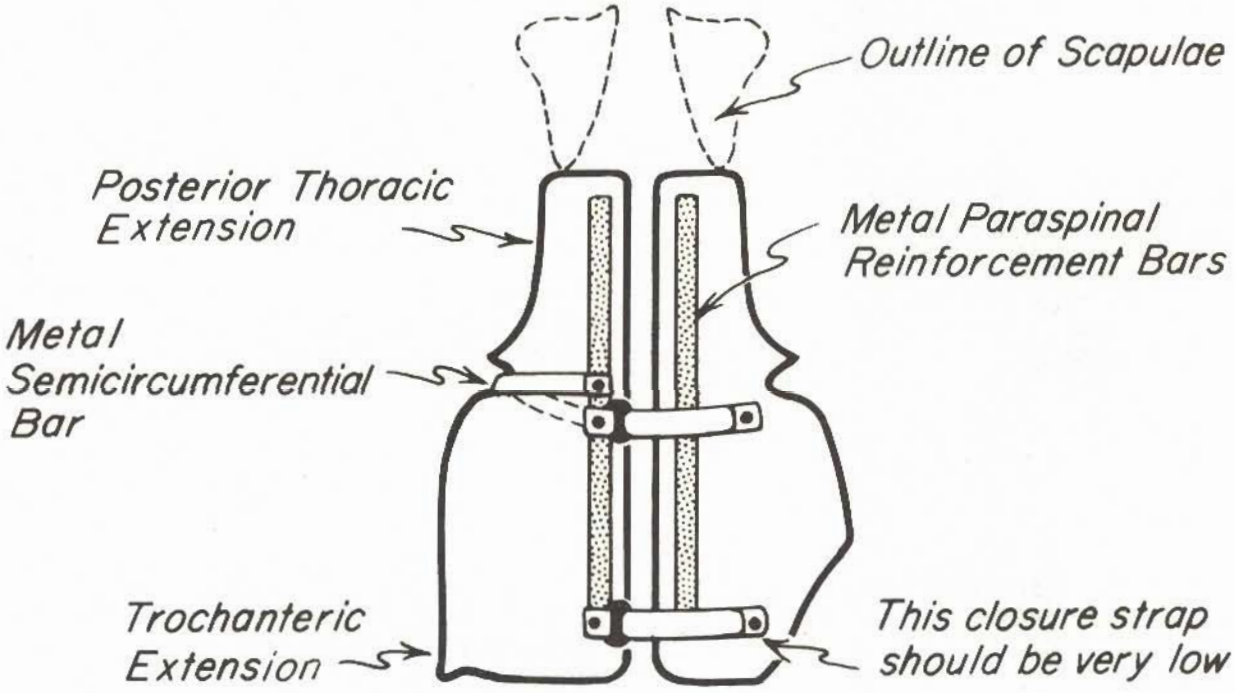

(posterior view)

Figure 7

MECHANICS

It is very important to understand the mechanics of treating lumbar scoliosis. This will allow us to approach each new problem in an organized, productive manner.

In this section, we will discuss the most important forces exerted between the body and the orthosis in the sagittal and coronal planes. We shall demonstrate the relationship of these forces to orthosis stabilization and design.

The three arrows (figure 8) represent the most important forces in the coronal plane. They are the lumbar force, F_L, the gluteus medius force, F_{GM}, and the trochanteric force, F_T. The body is, of course, exerting equal and opposite forces on the orthosis (figure 9). F_L is the

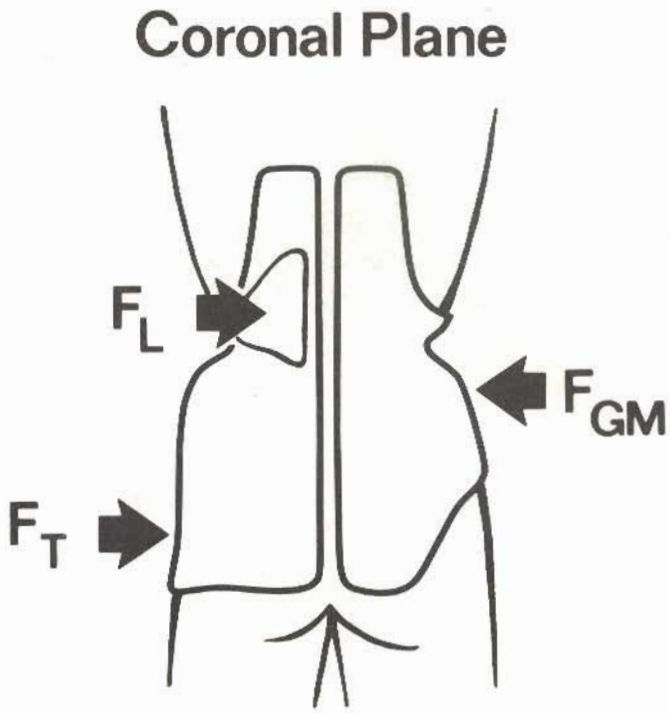

Figure 8

$$\Sigma M = 0$$

$$F_L \cdot y_1 - F_T \cdot y_2 = 0$$

$$F_T = y_1/y_2 \cdot F_L$$

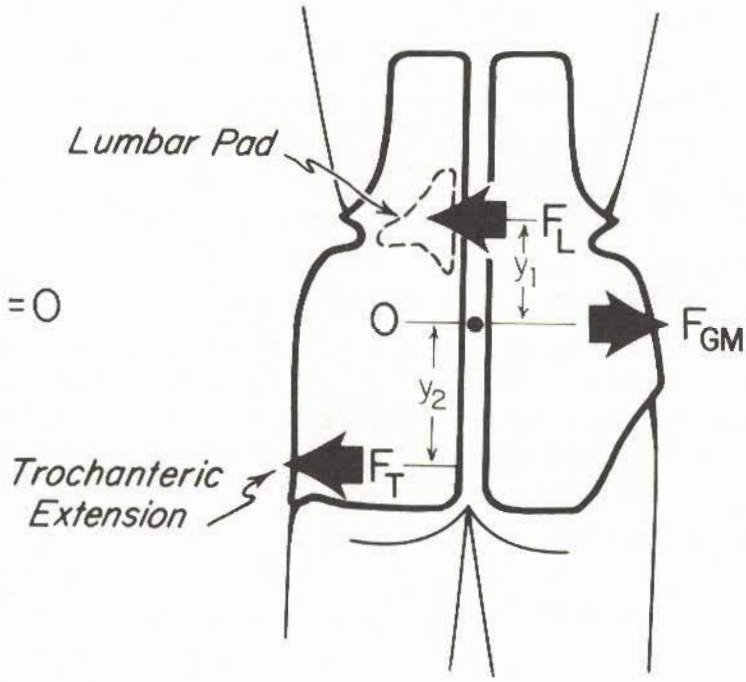

Figure 9

$$\Sigma M_O = 0$$

$$F_L \cdot y_1 - F_T \cdot y_2 = 0$$

$$F_T = y_1 / y_2 \cdot F_L$$

Without trochanteric extension the moment arm y_2 decreased. The orthosis is tipped in the coronal plane.

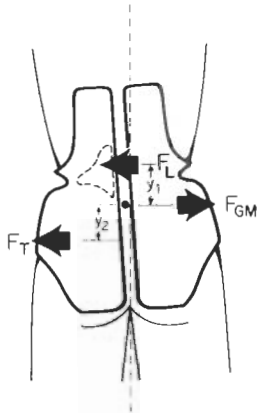

Figure 10

only directly therapeutic force of the three. It is generated by a lumbar pad pressing anteriorly and medially. This serves to derotate and translate the misaligned vertebrae back to their proper position. As the orthosis is cinched tight, the two other forces, F_{GM} and F_T will also be generated. F_{GM} is a force on the right hip in the area between the iliac crest and the trochanter. The third force, F_T, occurs in the area of the left greater trochanter. The top two forces tend to push the orthosis into a leftward list. The trochanteric force, F_T, serves to resist that action and maintain proper alignment of the orthosis.

If the trochanteric extension is absent, F_T must be generated along the lateral, inferior border of the orthosis just above the trochanter (figure 10). With a smaller moment arm, this force is not as effective in maintaining the alignment of the orthosis. The orthosis tilts, and the left lateral, inferior edge sinks into the soft tissues of the hip. The misalignment and discomfort limit the effectiveness of the orthosis.

Superior to the lumbar pad, the patient provides active control to maintain his head and shoulders in acceptable attitude and alignment. This active control cancels the need for another passive holding force on the right side above the lumbar curve. In fact, such a force will usually increase the leftward misalignment of the upper thorax (figure 11).

Figure 11

Leftward Misalignment Aggravated by Right Thoracic Pad

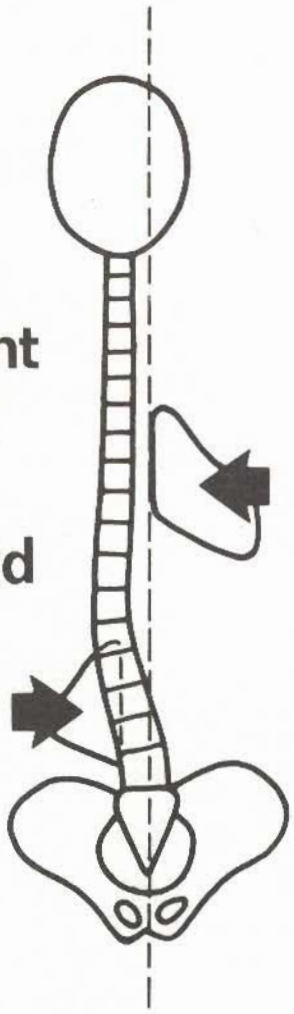

To examine the important forces in the sagittal plane, we use a lateral view of the orthosis (figure 12). Posterior pressure near the top of the thoracic extensions and near the bottom of the buttocks combined with firm abdominal pressure passively hold the lumbar spine in a relatively flexed position. This lumbar flexion brings the lumbar vertebrae to a more posterior location where it is possible to effectively push against them with the lumbar pad.

Proper maintenance of these forces, including the lumbar pad force, requires a stable posterior contour and a stable anterior-posterior dimension.

We have observed that large constant stresses on polypropylene at body temperatures will cause polypropylene to creep to a more relaxed configuration. This relaxation seriously affects the corrective force exerted by the orthosis. This is the reason for the metal reinforcement bars. The left para-spinal bar maintains

Figure 12

One Piece TLSO Mechanics in Sagittal Plane

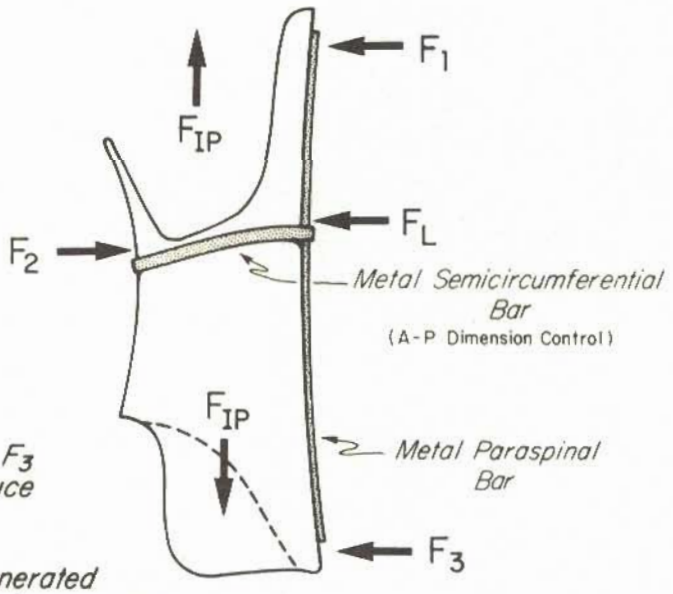

Forces F_1, F_2, F_3 passively reduce lordosis

F_{IP} forces generated by intra-abdominal pressure to distract spine

the contour supporting the lumbar pad. The right para-spinal bar maintains the relative void in the right lumbar area. The semi-circumferential metal waist bar prevents the orthosis shell from creeping to a larger anterior-posterior dimension and, thereby, losing the ability to exert an anterior force component. It is interesting to point out that the monel band served this purpose in the original leather Milwaukee girdle design.

Finally, we know that increasing intra-abdominal pressure superimposes a traction force and, thereby, partially unweights the spine. This obviously aids in curve correction.

This manual on the "Gillette" style Thoraco-Lumbo-Sacral Orthosis was prepared with the hope that it will contribute to an understanding of not only this orthosis but the general principles involved in treating lumbar and thoraco-lumbar scoliosis. In a companion manual, these principles are further developed within a more practical framework of specific fabrication directions.

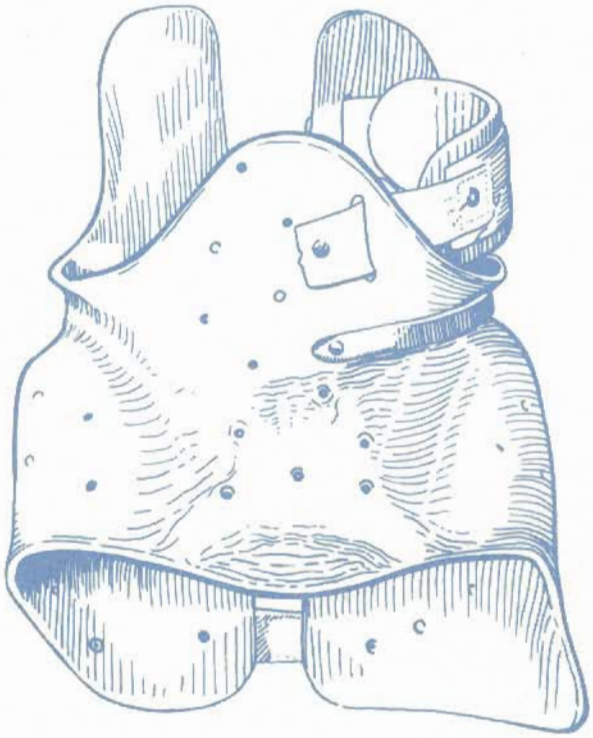

Author: J. Martin Carlson, M.S., C.P.O.
Director Orthotics and Prosthetics
Spinal Orthotic Team Leader: Chuck Schemitsch, C.O.
Model: Lori Schemitsch
Art: Carol Novak
Graphic Design: Candy Hollinger
Photography: Gordon Dunn, Chris Faust
Director of Medical Education: Robert Winter, M.D.
Chief of Spine Service: Robert Winter, M.D.

©Copyright 1980 by

Gillette Children's Hospital

the regional center for children and young adults with handicaps

200 East University Avenue
Saint Paul, Minnesota 55101
Telephone: 612/291-2848