

“ORTHOTIC MANAGEMENT OF THE LOWER LIMB OF CHILDREN WITH CEREBRAL PALSY”

Marty Carlson, CPO
Tamarack Habilitation Technologies, Inc.
1670 94th Lane NE
Blaine, MN 55449-4323

As we all know, the manifestations of cerebral palsy vary widely, and every child must be closely examined to evaluate his/her particular type and combination of pathological characteristics. However, a certain pattern of muscle imbalance is extremely common in children with cerebral palsy. At least part of this pattern is due to retention of primitive reflexes. However, some components of the muscle imbalance pattern suggest that non-pathological factors, muscle bulk and mechanical advantage, are also important in determining which muscle group dominates.

The pattern of deformity most commonly occurring in the lower extremities of children with cerebral palsy is seen in figure 1 and includes:

1. The subtalar joint is in valgus and the longitudinal arch is flattened on weight bearing;
2. The ankle tends to be plantar flexed;
3. The knee is flexed and;
4. The hip is flexed, adducted, and internally rotated.

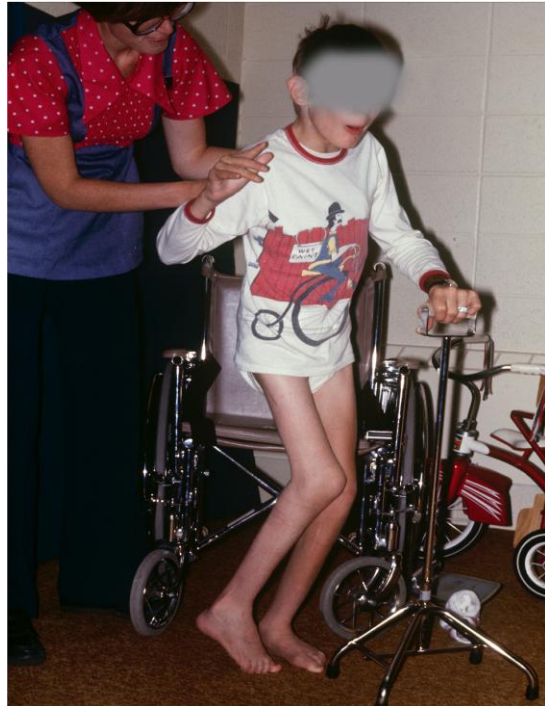

Figure 1

If the muscle imbalance persists without intervention, joint and bone deformities will develop and progress. We should also remember that orthotic treatment should never be an isolated intervention technique. It is combined with physical therapy and surgery as appropriate.

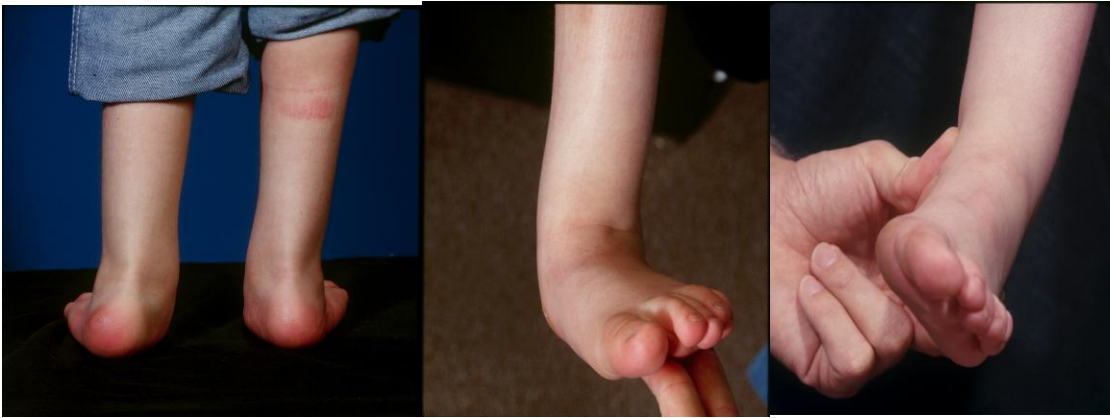

Figure 2

Orthotic treatment has three general goals:

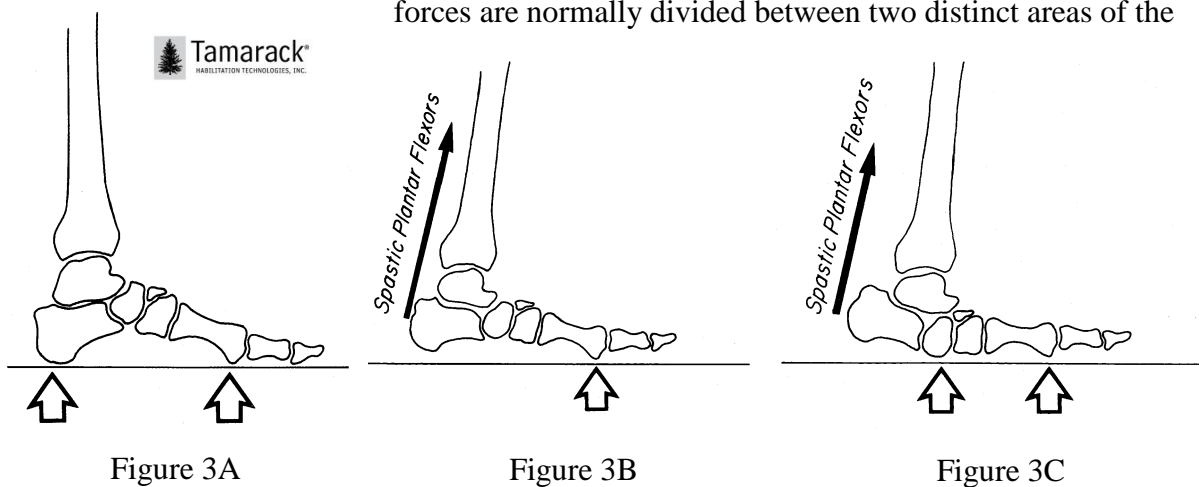
1. Prevent the development and progression of deformities from flexible to structural (especially during periods of rapid physical growth); Figure 2 is an example of flexible early deformity in CP
2. Provide support so the child can be more functional;
3. Provide external support following surgery to prevent either over-correction or recurrence of the deformity during the healing process.

Correction of a firmly established orthopedic deformity in the lower limbs of a child with cerebral palsy is seldom accomplished orthotically. For that reason it is not listed as one of our goals.

Every drug which goes on the market must be evaluated with respect to the side effects it produces. We must understand that orthoses have the potential to produce undesirable side effects also. Orthoses add weight, they may encumber, they take time and can even worsen deformities if badly designed/fit. With understanding, we can design to achieve or extend our goals while we minimize undesirable side effects.

Discussion of the specific joints will start at the child's foot and work upward to the hip.

The diagram in figure 3A illustrates how, during stance, most of the weight bearing forces are normally divided between two distinct areas of the



foot, the calcaneus and the metatarsal heads.

When the plantar flexor muscles are over-active, the hind foot is pulled upward out of contact with the floor (figure 3B) and the forefoot must take most of the weight. The body's center of gravity is shifted forward to maintain stability and it is a greater challenge for the child to maintain balance within a smaller base of support. The soft tissues which maintain the longitudinal arch are stretched. If these conditions persist, the longitudinal arch will be flattened. With growth and time, the long arch will be reversed, creating what we call the "rocker bottom" foot deformity seen in figure 3C.

Destabilizing Effects of Gravity and Achilles Tendon Tension

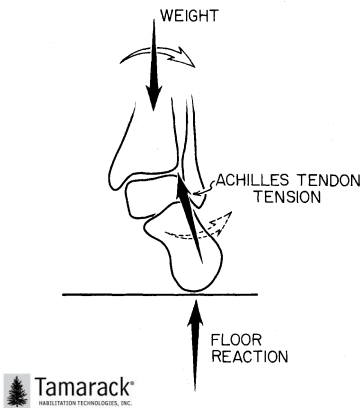


Figure 4

Figure 4 diagrams the deformity in the frontal plane. The foot inverters are overpowered and the subtalar joint tends to collapse into valgus. Both the weight bearing force and the Achilles tendon tension become valgus deforming forces when the inverters are unable to maintain proper M-L alignment of the calcaneus under the tibia. Figure 5 is an example of the consequences for a particular 10 year old.

We know that physical therapy forces to stretch the heel cord should not be applied to the forefoot alone. That does stretch the plantar flexors but also will exaggerate the

collapse of the subtalar joint (see figure 6). A skilled therapist will grasp the calcaneus to control the subtalar joint to make sure it doesn't collapse into valgus as the ankle is passively dorsiflexed (see figure 7). As orthotists, we should be aware that these principles

apply in orthotic design as well. An orthosis which is intended to resist plantar flexion must be designed to simultaneously control the subtalar joint and support the arch. If not, the orthosis will be needlessly contributing to the development of a foot deformity.

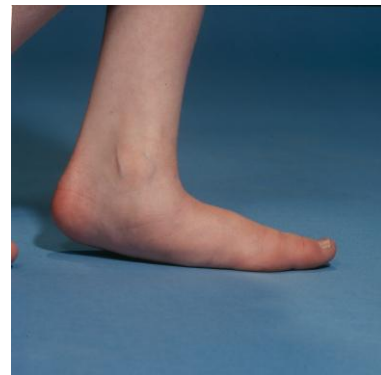

Figure 5

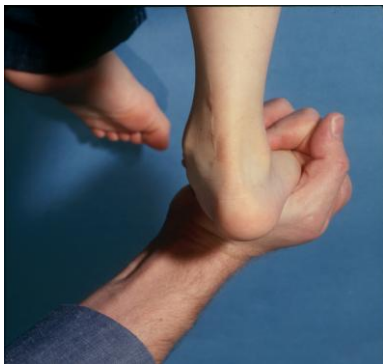

Figure 6

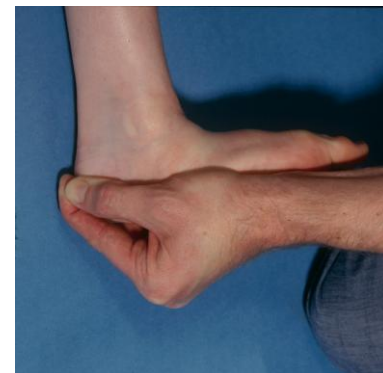

Figure 7

Figure 8 is another example of the classic rigid, post adolescent valgus "rocker bottom" feet. For many years this patient wore conventional double upright type Ankle-



Figure 8

Foot Orthoses attached to a shoe such as shown in figure 9. A medial “T” strap, is unlikely to effectively prevent the subtalar joint from collapsing into valgus.

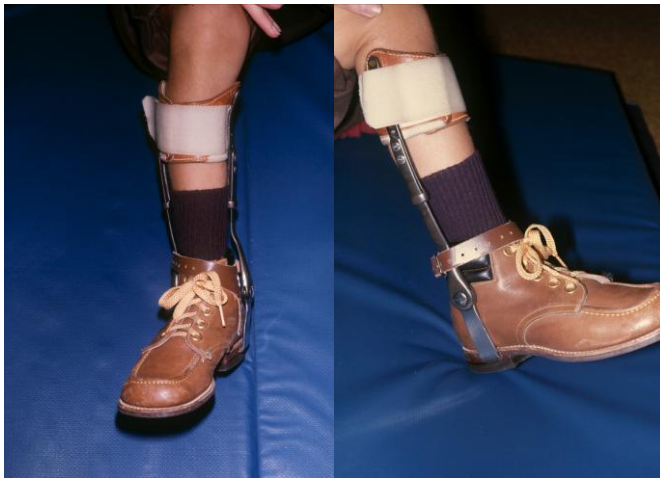

Figure 9

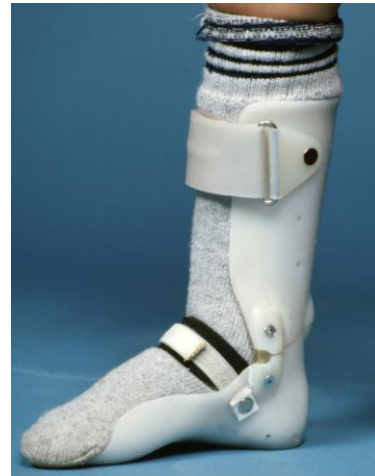

Figure 10

In North America, almost all current lower limb orthoses utilize the polypropylene shell design. These orthoses must fit the hind foot and mid foot very supportively. In a well designed AFO, an instep strap is installed as necessary to hold the

child’s heel down and back in the orthosis (see figure 10).

It is, unfortunately very common to think that neutral subtalar alignment can be

maintained by supporting the longitudinal arch of these developing children. That is wrong. Arch support relies on ligaments, most notable the Spring ligament, (see figure 11) to transmit that support back to the subtalar joint [Ref.1]. Over time, with growth and development these ligaments will be stretched, and the subtalar joint will collapse into valgus alignment in spite of support to the arch area.

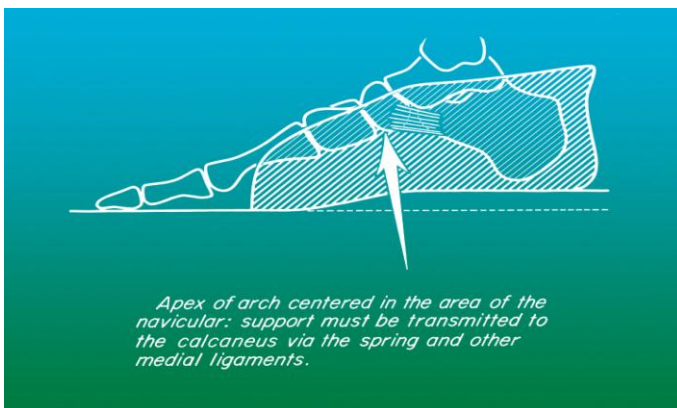


Figure 11

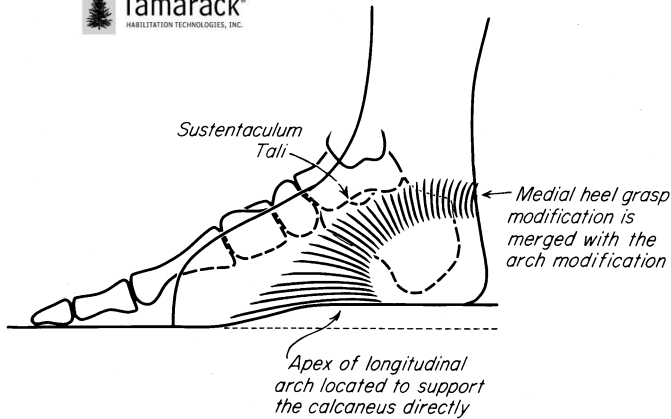


Figure 12

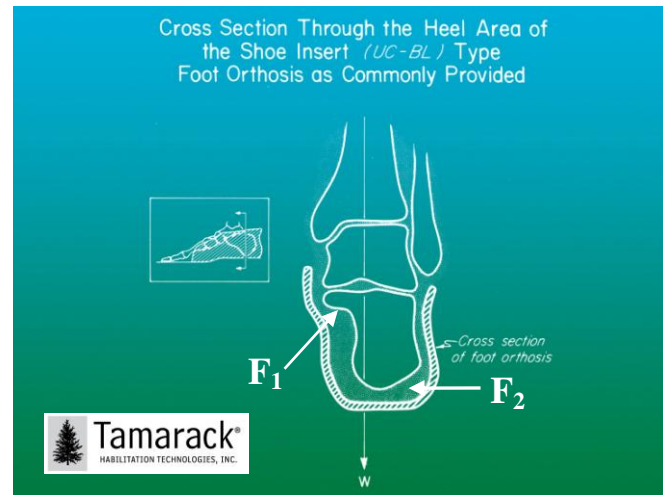


Figure 13

Figures 12 and 13 show the primary areas of medial stabilizing pressure, and figures 14 indicate the aggressive sculpting necessary to adequately grip the calcaneus to support the subtalar joint. This configuration of support is much more directly applied to the Sustentaculum Talus and Calcaneus.



Figure 14

There are times when we should be aware of the practical limits of orthotic treatment. When the heel cord of an ambulatory child is too tight to permit passive dorsiflexion to neutral with moderate force, even the most skillfully rendered orthotic treatment will fail in most cases, to achieve/maintain a plantargrade foot. That situation may call for surgical weakening of the plantar flexor muscles to gain adequate dorsiflexion range of motion without excessive heel cord tension. Active and passive examination of the lower limbs of a supine child is not only inadequate, but can actually be misleading. Observation of muscle activity, coordination, and spasticity during weight bearing is very important in making the correct decisions about treatment. Also, keep in mind that the child in clinic is not always typical of the child at home.

If your determination is that there is too much plantar flexion tone or inadequate ankle range to achieve a plantar grade foot (without unrealistic force or sacrificing subtalar neutral alignment), surgery may be advisable. If surgery is not performed, the calf

section of the AFO should be brought to the desired A-Alignment by means of a compensating posterior wedge added to the AFO or shoe. It should also be noted that if no significant dorsiflexion range is expected during ambulation (because of tone or contracture) it is probably counter-productive to articulate the AFO. Articulation causes extra unproductive skin pressure from subtalar support surfaces as the tibia moves into anterior alignment. Articulation may also reduce Gastrocnemius stretch during ambulation.

When the ankle has significant, useful dorsiflexion motion, we provide for that motion in the orthosis with ankle joints as you saw earlier (figure 10). We stop plantar flexion motion at the neutral (90°) position. It is typical for these children to have less lower limb muscle tone when crawling and climbing around toys and furniture than when they are upright and ambulating. Non ambulation hours make up the vast majority of their days. A well-designed, articulated AFO in these cases allows dorsiflexion ranging during those hours when tone is reduced.

Moving up to the knee, one of the most common and obvious observations is the crouched stance. Loss of full knee extension may be primarily due to tight hamstring muscles or it may have developed secondary to hip flexion contractures. Often, it seems, both factors contribute. Knee flexion is related to hip flexion because of the muscles they share and because of their need to compensate for one another in the achievement of balanced upright stance. Our examination should always determine, if possible, which postural deviations are structural and which are functional compensations. These considerations are, of course, of utmost importance whenever surgery is contemplated.

There are some common misconceptions about why many children with cerebral palsy stand and walk with knees flexed. One theory is that it is an attempt to lower the center-of-gravity to aid balance. That theory is hard to accept; even 50 degrees of knee flexion will lower the body center-of-gravity by less than 10%. Another statement, heard on occasion, is that the bent-knee stance results from weak quadriceps and strengthening exercises are recommended. This seems very improbable because a flexed knee stance, in itself, requires enhanced knee extensor strength (see figure 17). Low

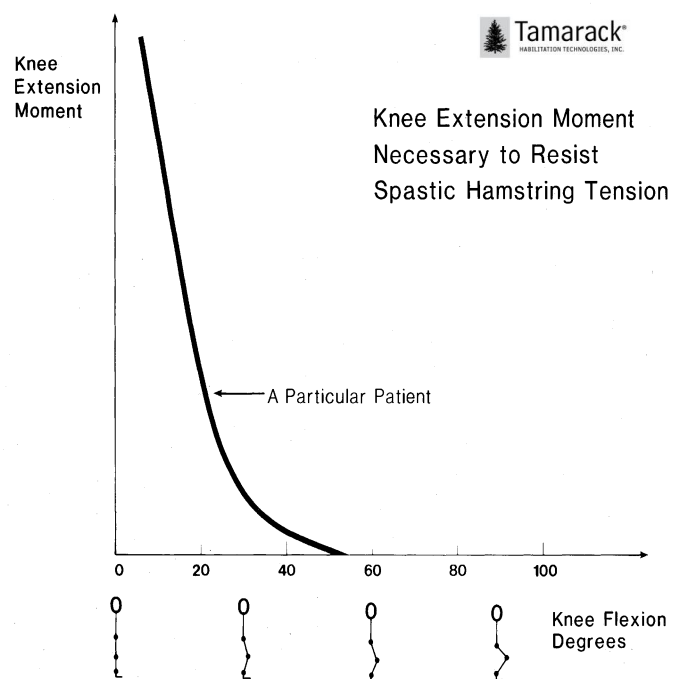
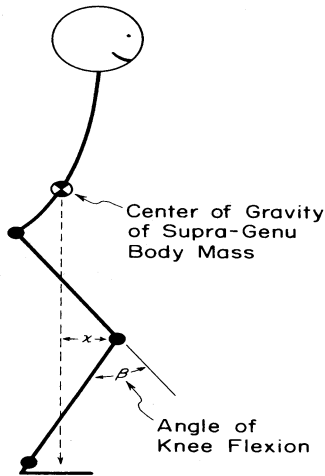


Figure 15

quadriceps tone/strength is not the problem.

We can identify several biomechanic factors that contribute to flexed knee stance. Hamstring tightness or spasticity is almost universally observed in these youngsters. The hamstrings are very strong, so this usually is the primary and major resistance to full knee extension. The graph in figure 15 qualitatively illustrates the rapid rise in that resistance as full knee extension is approached.



Tamarack® Figure 16

Straightforward mechanical analysis can relate knee flexion angle to the flexion moment at the knee caused by gravitational force on the body (see figure 16). For example, when 35 kgm., normal youngster, stands with knees flexed 50 degrees; his quadriceps must generate a moment of about 3 KgM just to offset the

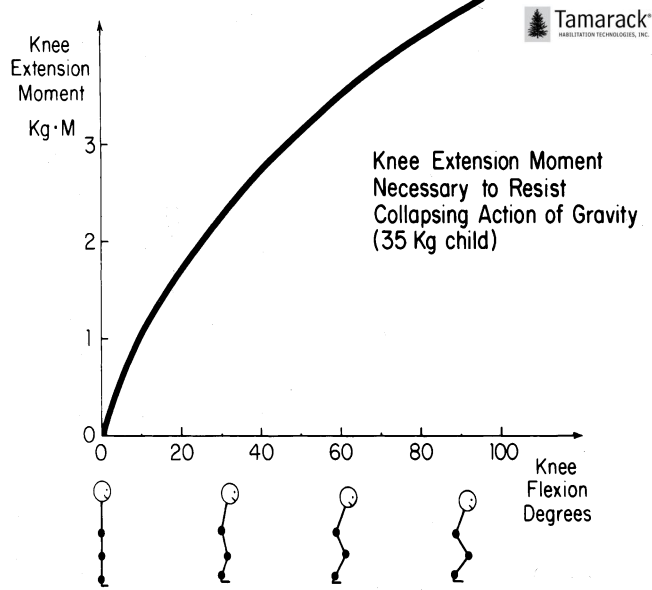


Figure 17

collapsing effect of gravity (figure 17). When the youngster stands in well-aligned full knee extension, virtually no effort is needed against gravity.

The graph in figure 18 looks at the combined effects of gravity and tight hamstrings as a function of knee extension. The dashed line is the sum of the two. The left side of the graph represents absence of crouch. The extreme right side of the graph again represents a deep crouch. As we follow the dashed line leftward, we see that, as the youngster straightens from the deep crouch, the necessary quadriceps effort decreases as the knee centers move closer to the weight line. However, at some

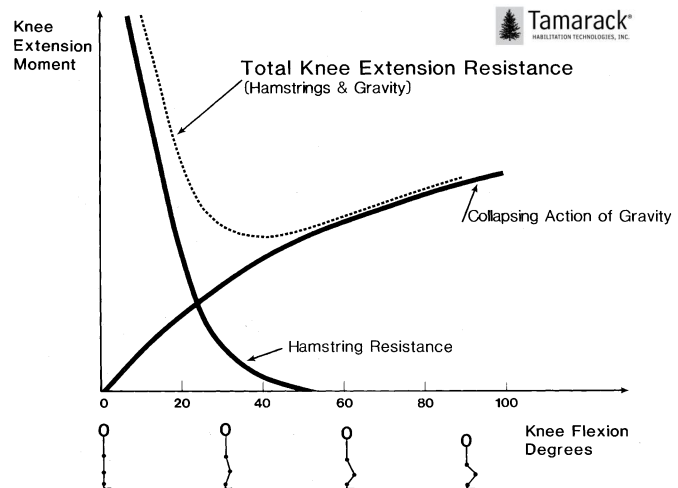
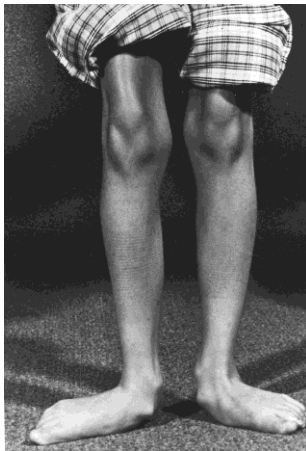

Figure 18

point the hamstrings begin to significantly resist knee extension, and that resistance may rise very fast as the knees approach full extension. Please note that the dashed line indicates the youngster will probably choose particular to stand, in this example, with knees flexed about 40°. Standing with either more or less knee flexion requires even greater quadriceps effort. Please also note that this analysis is qualitative. Each child represents unique muscle tone and contracture factors and will find his own particular stance or posture depending on those factors.

As the months and years progress, the extraordinary tension of the quadriceps will stretch and elongate the patello-tibial ligament. As the child grows, a patella alta condition develops. The photograph in figure 19 came out of an old medical chart. It was taken to document a case of severe foot deformity. However, notice the boy's knees. The patellae are riding entirely above the femoral epicondyles. The profile of the femoral condyles and the inter-condylar notches are clearly seen below the lower border of the patellae. The patello-tibial ligament has been stretched to perhaps twice the normal length.



The change in the position of the patella profoundly alters the mechanics and effectiveness of the quadriceps. It does so in several compounding ways:

1. As the patellar ligament lengthens, the resting length of the quadriceps muscle belly is reduced; the muscle is thus “weakened” similar to what happens in a surgical tendon lengthening procedure.
2. As the patella moves above the femoral condyles, the patellar ligament slips into a position in the femoral intercondylar groove where it has less mechanical advantage to create an extension moment. Figures 20 and 21 compare the normal with the patella alta configuration.

Figure 19

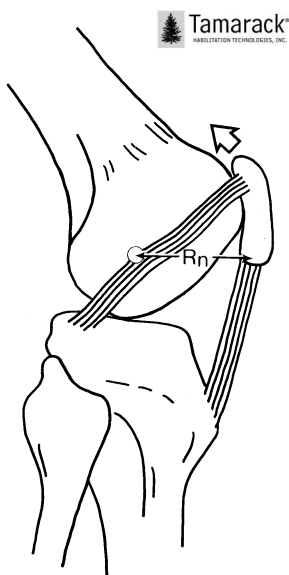
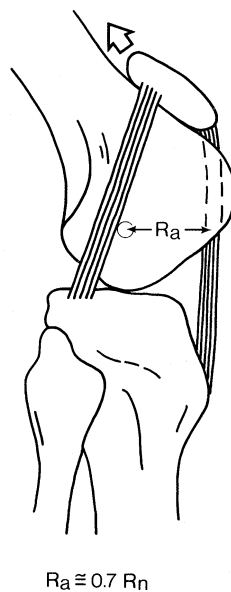


Figure 20



Page 8

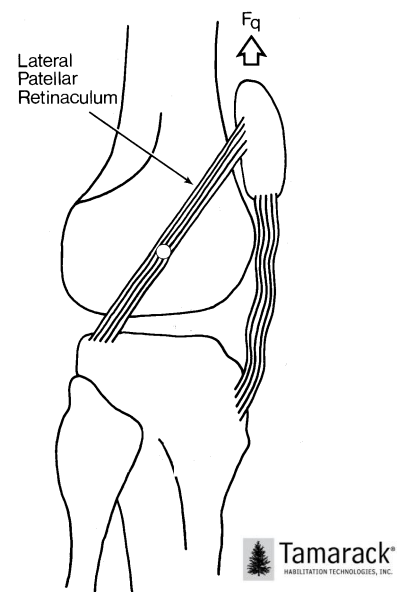


Figure 21

Note that, in the Patella Alta condition, the tendon, lying deep within the intercondylar groove, passes closer to the center of rotation. Thus the extension moment produced by any amount of quadriceps pull is reduced. This effect is greater as full knee extension is approached because the patella is then entirely above the condyles.

3. Because of the geometry and mechanics of the knee, as the patellar ligament lengthens, more and more of the quadriceps tension is transferred to the patellar retinaculum. Retinaculum tension is much less effective in extending the knees because these structures pass closer to the center of motion as you see in the diagram to your right. Because of knee kinematics, this transfer of tension from the patellar ligament to the retinaculum increases as the knee approaches full extension and there exists the situation diagrammed at the right side of figure 21. This tension transfer mechanism was pointed out by Dr. Eggers in 1950 [Ref 2.]. Note that both loss of mechanical advantage and tension transfer to the retinaculum are increasingly occurring as the knee approaches full extension.
4. A fourth factor is what happens to the force vectors of the Vastus medialis and

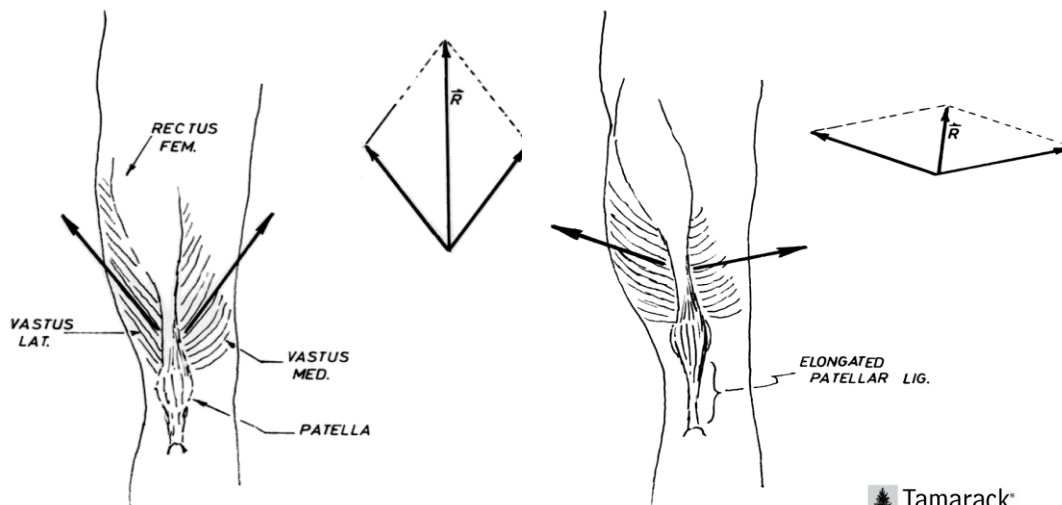


Figure 22

Vastus laterallus as the Patello-tibial ligament lengthens. As the Patella rises, the forces exerted by the two Vasti muscles become more and more oppositional rather than pulling mostly in the same direction (figure 22).

A teen-age youngster with tight hamstrings and patella alta will not be restored to acceptable knee function by surgical hamstring release alone for the biomechanical reasons just described. Surgical procedures such as reefing (shortening) the P-T ligament or relocation of the Tibial tubercle have been described. This has been proposed by Eggers and others but is not common practice in North America. Those surgeries may have been ignored or rejected for good reason, of course.

The graphs in figures 15, 16, 17 and 18 will vary from patient to patient and even for a given patient, according to level of spasticity and fatigue. This analysis is presented not as a quantitative tool. It was meant to help us analyze, only qualitatively, the biomechanics of what we observe.

The use of orthoses which cross the knee joint is advocated in the following instances only: 1. when the knee is passively fully extendable and supporting the knee significantly improves the child's ability to stand and ambulate; 2. to maintain the knee extension range of motion gained by surgical procedure; and 3. Night positioning to resist a progressive knee deformity.

We will turn now to orthotic treatment of the hip. In most cases it is impractical to attempt to control hip flexion or adduction during ambulation. The hardware necessary to achieve control is prohibitively bulky, heavy, and bothersome for the child to carry around. However, nighttime positioning orthoses do make sense in many cases for both marginal ambulators and non-ambulators. The hip and knee deformities we see developing in children invariably match the child's sleeping posture. If the sleeping posture does not initiate the deformities, it seems certain that maintaining those positions 8-10 hours every night will facilitate deformity progression.

It has been common practice in some places to apply abduction pillows or wedges to resist adductor tightness or following adductor tenotomy and obturator neurectomy. These abduction orthoses are ineffective. They do not control rotation and they do not prevent the adduction deformity from recurring on the side where spasticity/tone is most severe. We cannot expect to control hip position with an orthosis which does not cross the hip joint. The night time positioning orthosis must cross the hip. Children who begin to develop hip or hip and knee deformities can more successfully be provided with a

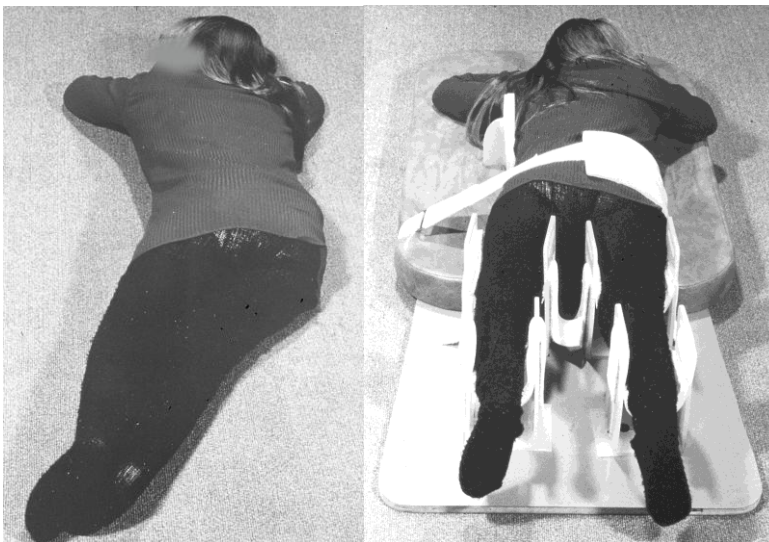


Figure 23A

Figure 23B

recumbent support orthosis (RSO) which maintains them in an extended/neutral or optimum attainable position during their recumbent hours. This type of orthosis can be fabricated in many configurations, depending on the deformity it is meant to resist. The design you see in figure 23B applies simple biomechanical principles to resist the habitual posture shown in figure 23A. Other designs may be rendered according

to the need. Recumbent Support Orthoses are relatively inexpensive and can

accommodate considerable growth. It is important to make the orthoses as attractive as possible so that parents, caregivers, and child will accept them. The Recumbent Support Orthosis may also be used to maintain desired positioning following hip and knee surgery.

Pommels, straps and bolsters can be used as part of the non-ambulatory patient's seating system, but their effect on hip adduction contractures is minimal because they cannot prevent the pelvis from rotating about the vertical axis allowing the more severe adduction contracture to create/maintain a "Windswept Hips" deformity.

A final comment on knee and hip deformities in non-ambulatory children should be made. Some of those who give medical care to these children feel that lower limb deformities are of no consequence if there is no possibility of ambulation. If that reasoning prevails, by the time the child is a teenager, the hip and knee deformities which result from such neglect are likely to be very severe. Efforts by caregivers to adequately position and provide nursing and toileting care for these people, either seated or recumbent, are greatly complicated and limited by the deformities. Gradually the deformities lead to a pattern which allows only a single recumbent posture. The result is greater care labor costs, and more frequent hospitalization for ulcer care. The long term cost to society is much greater because of that early neglect.

REFERENCES:

1. Carlson, J.M., and Berglund, G., "An Effective Orthotic Design for Controlling the Unstable Subtalar Joint", Orthotics and Prosthetics, Vol. 33, No. 1, pp. 39-49, March 1979.
2. Eggers, G.W.N., "Surgical Division of the Patellar Retinacula to Improve Extension of the Knee Joint in Cerebral Spastic Paralysis", Journal of Bone and Joint Surgery, Vol. 32-A:80, 1950