February 2011 ■ Vol 7 No 1

The ACADEMY TODAY

Advancing Orthotic and Prosthetic Care through Knowledge

Features

Lower Limb Prosthetics Society

Skin and Soft Tissue Management

The Mechanics of Soft Tissue Damage: Removing the *"Teeth" from the Rub*

Soft Tissue Revision of Amputated Limbs

Treating Skin Conditions of the Amputee

Read the articles and visit the Academy Online Learning Center to take the quiz and earn credits.

THREE Continuing Education Opportunities in this Issue!

American Academy of Orthotists and Prosthetists ■ 1331 H Street, NW, Suite 501 ■ Washington, DC 20005 ■ www.oandp.org
Supplement of *The O&P EDGE* ■ Published by Western Media LLC

Contents

February 2011

Message from the President A-3

Are We There Yet?

Features

Lower Limb Prosthetics Society

Introduction: Skin and Soft Tissue Management A-4

The Mechanics of Soft Tissue Damage: Removing the "Teeth" from the Rub A-5

Soft Tissue Revision of Amputated Limbs A-8

Treating Skin Conditions of the Amputee A-11

Grant Update A-15

The Academy Grant: A Plan for Continuing Initiatives

Indicates continuing education opportunity on the Online Learning Center at www.oandp.org

Copyright 2011, American Academy of Orthotists and Prosthetists Inc., 1331 H Street, NW, Suite 501, Washington, DC 20005. **Phone: 202.380.3663; Fax: 202.380.3447; www.oandp.org.** All rights reserved. No part of this publication may be reproduced without written permission from the publisher. Letters to the editor and other unsolicited material are assumed to be intended for publication and are subject to editorial review, acceptance, and editing.

The ideas and opinions expressed in *The Academy TODAY* do not necessarily reflect those of the Academy, the editor, or the publisher. The acceptance of advertising in no way implies endorsement by the Academy, the editor, or the publisher.

Published by Western Media LLC, 11154 Huron Street, Suite 104, Northglenn, CO 80234. Phone: 303.255.0843; fax: 303.255.0844; e-mail: info@opedge.com

EDITORIAL STAFF

Editor
Manisha S. Bhaskar

Managing Editor
Miki Fairley

Contributing Editors
J. Martin Carlson, CPO, FAAOP
Christian Ertl, MD
Clay Kelly, MD

2010–2011
BOARD OF DIRECTORS

President
Scott D. Cummings, PT, CPO, FAAOP

President-Elect
Mark D. Muller, MS, CPO, FAAOP

Vice President
Bruce "Mac" McClellan, CPO, LPO, FISPO

Treasurer
Michelle J. Hall, CPO, FAAOP

Immediate Past President
Keith M. Smith, CO, LO, FAAOP

Executive Director
Peter D. Rosenstein

Directors

Michael J. Allen, CPO, FAAOP
Kevin M. Carroll, MS, CP, FAAOP
Donald R. Cummings, CP, LP
David M. Gerecke, CPO, FAAOP
M. Jason Highsmith, DPT, CP, FAAOP
Phillip M. Stevens, MEd, CPO, FAAOP

Volume 7 ■ Number 1

The ACADEMY TODAY

1331 H Street, NW, Suite 501
Washington, DC 20005
202.380.3663 ■ Fax 202.380.3447
www.oandp.org

Message from the President

Are We There Yet?

Perspective can be a tricky thing. When he was five years old, my son was getting a ride in an old car that did not have the electric windows he was accustomed to. After rolling the windows up and down a few times, he concluded that the manual windows were better "because they can go up and down without turning on the car." I would like our members to take a minute to consider what it is we do and how we might be viewed from the perspective of others. Are we makers of devices as the term "industry" would imply, or are we in the business of providing care as the term "profession" would imply? In considering the various definitions of "profession," I have chosen to include one from the Australian Council of Professions. I have underlined what I perceive to be the critical indicators for creating a good match with O&P.

"A profession is a disciplined group of individuals who adhere to ethical standards and who hold themselves out as, and are accepted by the public as possessing, special knowledge and skills in a widely recognized body of learning derived from research, education, and training at a high level, and who are prepared to apply this knowledge and exercise these skills in the interest of others. It is inherent in the definition of a profession that a code of ethics governs the activities of each profession."

We find ourselves in a bit of a conundrum because the significant technological advances in the design of O&P devices is so newsworthy that it would seem to minimize the importance of the primary factor that determines optimal care, namely the application of our expertise (special knowledge and skills) when providing these devices. Often, it is not understood that the technology is only as good as the expertise that is utilized when providing O&P care. The resultant situation places an overreliance on the device and "what it can do." This reminds me of a similar dynamic that occurs with some regularity in my home state of New Hampshire when a hiker needs to be rescued from the mountains—he has the new GPS to determine his exact location but does not know how to navigate the terrain to find his way out.

As O&P embraces the dramatic improvements to the design of our device options, it must be recognized that the device alone will not be responsible for improving outcomes. Instead, these more sophisticated design options need to be thoughtfully considered by knowledgeable practitioners who understand not just the potential benefits but also the potential downsides and the often-complicated relationship between the two. The gradual transition to evidence-based practice (EBP) will help us find the balance with these options by allowing us to combine documented scientific knowledge with our own experience. Ethically applied to individual patient circumstances, this knowledge and experience will result in optimal care. Another benefit of utilizing EBP is the ability to justify our interventions through the use of scientific data. This makes good medical sense *and* good business sense.

Scott D. Cummings, PT, CPO, FAAOP
2010–11 President

During his tenure as Xerox president in the 1970s, Alan Kay said, "The best way to predict the future is to invent it." Yes, perspective can be a tricky thing, but if we stop to consider that to serve our patients best in the future, we will need to focus not so much on the device but on how we manage the care associated with the provision of that device. Only then will we prevent being stigmatized as vendors, a situation that relegates the device to a commodity item that can be bid on. Only then will we be comfortably functioning in the realm of a true O&P profession.

On trips, my son used to ask, "Are we there yet?" Almost. To advance the profession we need to continually advocate for higher standards in the way we acquire and apply knowledge. Improving the quality of applicants to O&P schools and then providing the appropriate education, residency, and credentialing opportunities will create the professional workforce of the future, a future that relies on science as much as art. If we are to avoid being viewed and thus compensated by virtue of the device we deliver rather than the care we provide, then we must embrace the concept that it is our special knowledge and skills that we need to leverage. Our future as a profession depends on this—and our patients deserve nothing less.

Skin and Soft Tissue Management

Introduction


Carroll


Rheinstein

One of the biggest challenges in providing care to people with amputations is keeping their skin and soft tissue healthy. In spite of advanced materials and socket technologies, patients can experience skin breakdowns and dermatological concerns as well as problems with deep tissues and bones. Effective treatment rests on determining the source of the problem. Is it the prosthesis, factors within a patient's residual limb, or a combination of both?

The objective of this issue of *The Academy TODAY* is to highlight current understanding and approaches to skin and soft tissue difficulties. We hope this information will lead to better clinical decision-making including understanding when patients should be referred back to their physician for care.

A goal of this issue of* The Academy TODAY *and the Lower Limb Prosthetics Society is to foster effective dialog between prosthetists and physicians treating people with amputations.

In this issue we are pleased to present articles that focus on these topics:

- "The Mechanics of Soft Tissue Damage: Removing the 'Teeth' from the Rub," by J. Martin Carlson, CPO, FAAOP.
- "Soft Tissue Revision of Amputated Limbs," by Christian Ertl, MD.
- "Treating Skin Conditions of the Amputee," by Clay Kelly, MD.

A goal of this issue of *The Academy TODAY* and the Lower Limb Prosthetics Society (LLPS) is to foster effective dialog between prosthetists and physicians treating people with amputations. Frequent updates about patients' status by e-mail, phone, or fax lead to better decision-making and builds professional relationships. We encourage prosthetists to initiate these communications. If a surgical revision is indicated, preoperative discussions can assist in surgical planning and the coordination of care. Continual improvement in amputation treatment can be achieved when surgeons, other physicians, therapists, and prosthetists provide feedback to one another as to their patients' progress.

Please distribute this issue to surgeons who perform amputations and to physicians and therapists who care for patients with amputations, diabetes, and vascular disease.

This edition of *The Academy TODAY* is sponsored by the Academy's Lower Limb Prosthetics Society, and by ALPS, who wants to improve care for people with amputations. How can you help with this effort?

Kevin Carroll, MS, CP, FAAOP
John Rheinstein, CP, FAAOP

The Mechanics of Soft Tissue Damage: *Removing the "Teeth" from the Rub*

■ J. Martin Carlson, CPO, FAAOP

The materials that form the interface between skin and structural support surfaces of orthotic and prosthetic devices are extremely important. Their physical characteristics determine our patients' comfort levels and, in many cases, the safe function of their devices. We are very accustomed to comparing the cushioning characteristics of interface materials. We intuitively equate cushy with comfort. There is an equally important second material characteristic, which is related to friction.

Repeated stresses upon and within the skin and soft tissues give rise to "hot spots" that cause discomfort and limit function. These stresses occur because skeletal elements are moving within a containment structure. When our patients push on in spite of the pain or because of sensation loss, open trauma may result (Figure 1).

Figure 1: An example of trauma caused by excessive friction/shear forces. The amputee had impaired sensation due to peripheral neuropathy.

The everyday term for this is "rubbing." We all have experienced this from time to time inside our ski boots, under the straps of a backpack, or with our thumb against the handle of a golf club, rake, canoe paddle, shovel, etc. Gloves and socks help, but rubbing can do damage even if there is nothing sliding against the skin surface. Rubbing just needs to pull against the skin enough times and with enough force to begin to break it down. Friction is the force that exerts pull/traction on the skin.

S. William Levy, MD, a dermatologist who specialized in the skin problems of amputees, cites rubbing, friction, and shear as being causative factors in the generation of blisters, follicular hyperkeratosis, callosities, and epidermoid cysts.[1,2]

Paul Brand, MD, the orthopedic surgeon who spent his life caring for people with neuropathic wounds, wrote, "There are two types of force which occur on the sole of the foot: one is vertical force at right angles to the foot, which causes direct pressure on the tissues. The other is horizontal force, or shear stress, which is parallel to the surface of the foot and occurs in association with acceleration and deceleration. Of the two forces shear stress is more damaging than pressure…."[3]

When discussing forces upon the surface of the skin, the terms "friction force," "shear force," and "traction force" are, as used in medical literature, essentially the same. The term "shear stress" is a bit different because it refers to force per unit of area. The medical literature has been a little loose in the usage of these terms, but that has not caused any significant misunderstanding.

The pull or traction force that an interface material will exert on the skin is determined by several factors:

- The amount of relative movement occurring between skeletal elements and the device.
- Thickness and mobility of the skin and soft tissue.
- The coefficient of friction (COF) of material interfaces between the skin and the support surface.
- Shear modulus of any "liner" type interface material.
- Moisture.

Relative Movement within the Device

Since the amplitude of skeletal motion inside a well-made device is not large, the skin surface, even in trouble areas, may not actually slide against the inside surface of the prosthetic socket, orthosis, or shoe. Sliding is not required for skin damage to occur. A thin layer of skin and soft tissue between the bone and support surface will experience large shear distortion even if the amplitude of bony movement is quite small. Shear distortion creates shear stress in the microstructures of the skin and soft tissue. When these stresses are sufficiently large and/or repetitive, microscopic tears occur in the tissue and grow as the stress cycles continue.

Minimizing "pistoning" and other relative movement of bone within the containing device is critically important and is achieved by optimizing the volume and the internal contours of the device as well as by employing appropriate suspension.

Thickness and Mobility of Soft Tissue

Excessive "wear and tear" on skin and subcutaneous tissue occurs primarily at bony areas rather than where there is a thick layer of cushioning soft tissue. When the bone moves within a device and the skin does not, the soft tissue between is subjected to the shear distortion needed to accommodate that situation. At locations where the soft tissue layer is thinner, there is greater potential for tissue damage because the

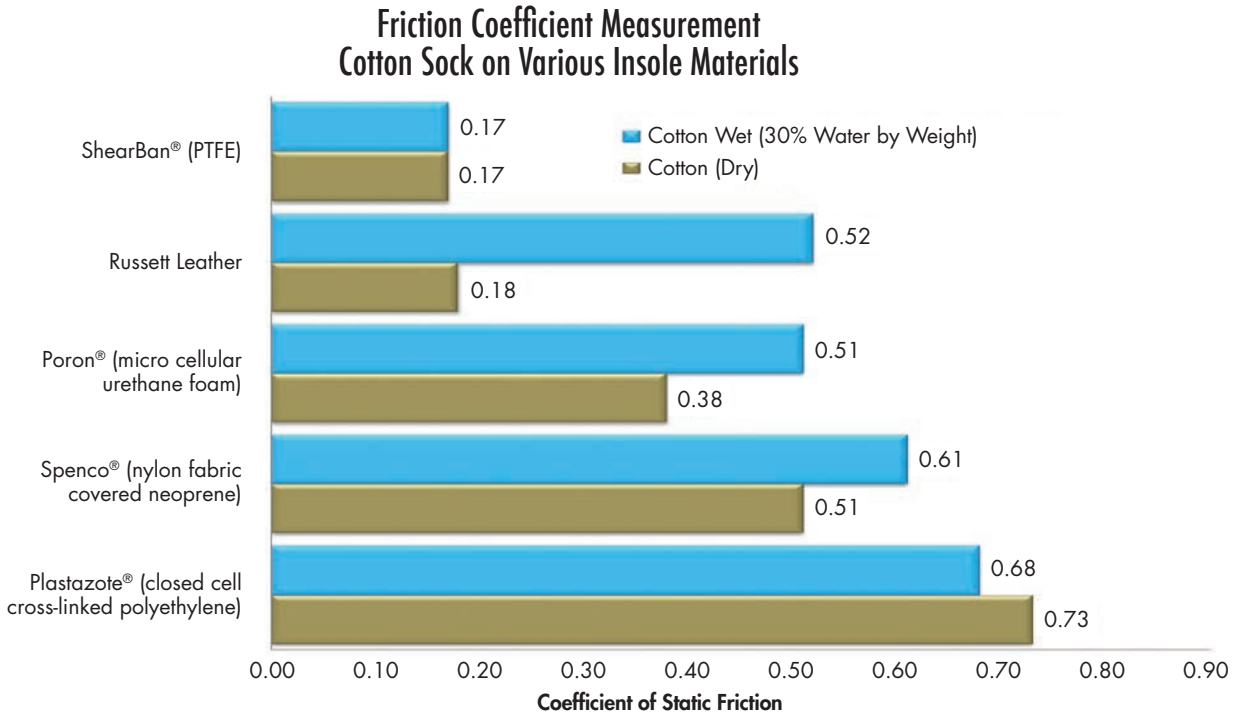

Figure 2: This bar graph compares COF measurements for a knit cotton sock material bearing upon a variety of common support surface cushion materials. *Source: Tamarack Habilitation Technologies.*

total shear distortion must take place within that thin layer. Both high pressure and high shear tend to occur at bony areas.

Soft tissue thickness and skin "mobility" sometimes go together and sometimes do not. If skin is "mobile," it is able to move back and forth with relatively little resistance. This characteristic tends to protect the tissue from damaging levels of shear forces. When the skin is less mobile, tissues will experience higher shear stresses. Grafted skin and adhered scars are examples of tissue that has very little mobility. The following quote from renowned foot-wound specialist Brand gives an elegant explanation of how this elevates and concentrates shear stress:

"When it comes to shear stress a scar behaves completely different[ly] from normal tissue around it. Normal skin is connected to the bones and ligaments by a rather loose web made of strands of collagen fibers woven around little cells of fat. When there is horizontal thrust imposed on the foot and the skin is subjected to the forces of acceleration, or of deceleration, all of the rather loose fibers come under stretch and the skin is able to move over the bones to the extent of perhaps 1cm backwards or forwards. In this way the forces that are applied to the skin are gradually transmitted to the skeleton, or vice versa, and no damage occurs.

"However, when one small piece of skin has healed after being ulcerated, it will often attach to the bones by short dense fibers of a newly formed scar. These fibers are not loose; they are tight. They are not long; they are short….

"Since the scar is the only part of the skin which is not able to move over the bone, the scar serves as an anchor and absorbs all the force of the shear stress, because its fibers are the only fibers that will not allow the skin to move on the bone. Thus it concentrates stress and the tissues are torn. The wound is often reopened and forms a fresh ulcer."[3]

Friction Characteristics of Materials

Prosthetic, orthotic, and pedorthic professionals have long focused on pressure as a problem, but this is only half of the equation. Friction is equally destructive. It is what puts the "bite" into a rub. A masseur uses oil to reduce that bite to a tolerable level. To really understand the destructive potential of friction, consider two new internal combustion engines. One has been properly filled with oil and grease. The other was assembled dry and has no lubricant. The first engine will perform powerfully for thousands of hours. The other will be severely damaged after only minutes. The difference is not contact pressure levels. The difference is that lubricant has reduced friction/shear forces between contact surfaces to almost zero in one of the engines.

We cannot fill our clients' sockets or shoes with oil and grease. That would be a bit messy and might create a suspension problem. What we can and should do is what the auto designers do. They reduce friction in some places and

definitely not in others. They want friction between clutch plates, between brake pads and disks, fan belts and pulleys, tires and pavement. Friction serves a vital purpose in those locations.

You may say, "But there is a lot of sliding motion in an engine. That sort of thing doesn't happen within a socket, orthosis, or shoe." But it isn't the sliding per se that does the damage. It is the shear stresses caused by friction that do the damage. In fact, friction builds to a maximum just before sliding occurs.

Figure 2 is a bar graph of our measured values for a cotton sock bearing against several different common cushion materials. What really stands out on the graph is the extremely low COF of polytetrafluoroethylene (PTFE) film under both dry and moist conditions.

Figure 3: An example of the strategic use of low-friction interface material to reduce peak friction/shear forces in specific at-risk locations.

A small, low-friction interface patch placed on the weight-bearing surface at the bony "hot spot" (Figure 3) acts like a patch of dry grease. The "grease" frees the skin (and sock) to glide back and forth with the bony movement. In slightly more technical terms, the very low COF of the patch releases the skin and sock before friction and shear stress reach damaging levels. The release and small amount of sliding only occur in the immediate area of the low-friction patch. Elsewhere, the anchoring effect of friction is unchanged.

Shear Modulus of Liner (or Insole) Material

The two fundamentally different materials in common use for socket liners, insoles, and general orthotic padding are plastic (polyethylene, polyolefins, ethylene-vinyl acetates [EVAs], etc.), foam materials, and gels (such as the low-shear modulus silicon and urethane compounds). The plastic foam materials have a much higher shear modulus than the gel materials. The low shear modulus of gels means that they act like an extra layer of soft tissue. They absorb some of the shear motion so the living soft tissue undergoes less shear distortion and less shear stress. The semi-liquid (incompressible) nature of gels coupled with their low shear modulus also gives them cushioning qualities that exceed compressible foam cushion materials. The gel material actually exhibits some ability to be pushed from areas of highest pressure toward neighboring areas of lower pressure. The perimeter bulge enlarges the "cradle of support" area and lowers pressure at the apex.

However, the benefit of gel material is proportional to its thickness. Thin gel layers give very little protection, so most liners are at least 6mm thick. The extra volume and weight are not a problem in many applications but not the best approach for all. Gels are also not very strong. They will fracture and crumble over time in some applications.

The COF of gels are typically very high, but if the gel material is thick enough, it absorbs much of the shear displacement that would otherwise happen within the patient's soft tissue. That reduces the need for friction protection.

Urethane and rubber foams have a lower shear modulus than the other foam cushion materials we commonly use. They absorb shear better but do not approach the shear and cushioning properties of the gels.

Moisture

The presence of moisture causes problems in two ways. The outermost layers of skin are physically weaker and more easily damaged when wet than when dry.

The second factor is the effect moisture has on friction. The COF exhibited by most of the materials common to O&P increase when moisture is present. Knowing this and the fact that moisture is often present inside our devices, COF values under both dry and moist conditions were measured and represented on the Figure 2 graph.

Conclusion

Friction, like pressure, is not all bad. It should be addressed at specific locations where it is excessive. Biomechanical principles relating to anatomy, pressure, and friction dictate that high friction/shear force peaks will occur (in most instances) at bony locations where peak pressures also occur. High friction/shear force and their damage will sometimes also occur in the immediate area of the socket brim.

We have long approached pressure strategically. That is, we off-load pressure at specific locations where we have reason to believe that this will be beneficial. We can and should use the same thinking with excessive friction/shear loads. When faced with a hot spot, wound, skin graft, or scar, we need to realize we have two tools in our toolbox: pressure off-loading and friction off-loading. We have the choice to use one or the other or both.

References

1. Levy SW. Skin Problems of the Amputee. St. Louis, MO: W. H. Green Inc.;1983:100–121.
2. Levy SW. Skin of amputees: the need for prosthetic care. *O&P Business News.* 2001:36–40.
3. Brand PW. Neuropathic ulceration. Reprinted in *The Star,* National Hansen's Disease Center. 1983:May–June.

J. Martin Carlson, CPO, FAAOP, is the president of Tamarack Habilitation Technologies Inc., a manufacturer of shear-reducing products such as ShearBan®.

Soft Tissue Revision of Amputated Limbs

■ Christian Ertl, MD

Caring for prosthetics patients who have recurrent skin breakdown or enduring pain is difficult. Dedicated prosthetists spend many hours making adjustments and multiple sockets for patients with persistent problems; however, when conservative measures have been exhausted, the next course of action is to refer them to an experienced physician to be evaluated for revision surgery or other medical treatment.

The decision to revise an amputation surgically is not taken lightly and is based on several complex factors. These include medical and prosthetic history, physical and diagnostic findings, as well as each patient's personal needs and goals.[1,2,3]

Important facts that will inform the decision to revise a patient's residual limb include location and frequency of skin breakdowns, specific description of pain, volume changes, and patient compliance.

Medical and Prosthetic History

Relevant information should be gathered from as many sources as possible so that the decision to operate is not made in a vacuum. When evaluating a patient for surgical revision, we typically start with the broad medical history and then focus on the details of prosthetic use, including the patient's state of mind. In this process, it is always best to engage spouses, relatives, and everyone who provides care to the patient. Immeasurable insight can be gleaned from the patient's initial walk through the office door. Physical signs can include limping, using a cane/crutch, or exhibiting a change in behavior not noticed during previous visits. It is imperative that providers have open communication with their patients. This means asking pointed questions that can help us understand patients' symptoms and their point of view. Patients may not know how to tell you that they are not wearing their prosthesis, and many believe that their discomfort is normal. Questions such as, "Is there anything else bothering you?" and "What is it you don't want to tell me?" can help reveal details that are critical in determining the correct course of action.

Active communication between the prosthetist providing regular care and the surgeon is critical to a good outcome. As a "frontline" provider, prosthetists are uniquely obligated to have regular and frequent contact with their patients. As such, they can observe the normal dynamic changes that occur while a residual limb matures as well as any abnormal events. The prosthetist's referral to a physician is best accompanied by a report with details about the history of all procedures and adjustments performed. Important facts that will inform the decision to revise a patient's residual limb include location and frequency of skin breakdowns, specific description of pain, volume changes, and patient compliance. A consultation with the patient together with the doctor and the prosthetist can be most useful.

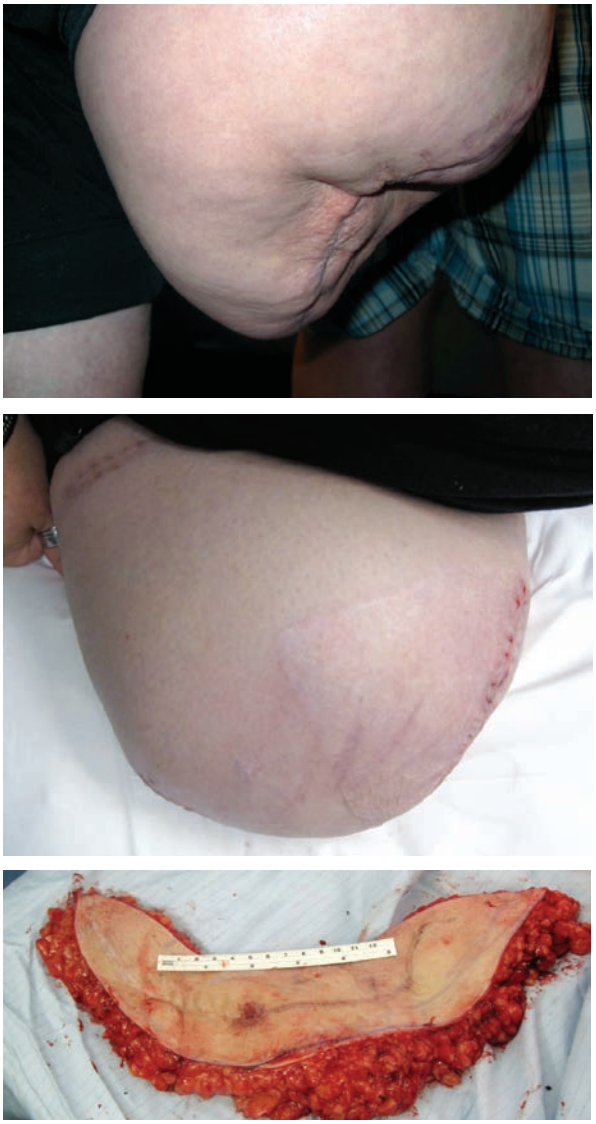

Case 1 (described on pg. A-10): Before revision surgery (top). After revision surgery (middle). Redundant tissue removed (bottom).

Physical and Diagnostic Findings

Referral for soft tissue revision should be contemplated on patients with the following scenarios:

- Chronic, non-healing ulcers despite off-loading and advanced wound-care treatment.
- Bony prominences or overgrowths, especially with thin, soft tissue coverage.
- Pain that persists even after the prosthesis is removed.
- Excess of redundant skin or soft tissue that pleats and folds, making hygiene very difficult, or which results in prosthetic instability.
- Adequate prosthetic fit cannot be obtained despite the patient having multiple adjustments, socket changes, and trying various prosthetic systems.

Even higher-functioning amputees can benefit from myoplastic revision (see *The Academy TODAY,* February 2010). In my experience, this surgical procedure usually results in fewer socket problems and improved coordinated muscle control, which permits patients to increase their physical activities. This is especially evident among those patients who require a prosthetic socket design with high proximal pressures to compensate for their lack of distal end-bearing capacity.

A thorough physical exam is imperative for an accurate diagnosis and treatment plan. Laying hands on the patient and palpating the underlying anatomy is an art that is sometimes overlooked, yet it is a very important part of a complete evaluation. This exam helps to determine if a patient's problem requires only a simple procedure such as the excision of a neuroma, a superficial scar release, or a more extensive revision and reconstruction surgery.

Patients must be appropriate surgical candidates before being considered for a revision procedure. Elderly, debilitated, or dysvascular patients may not survive general or even regional anesthesia needed to undergo an extensive revision. Those with severe congestive heart failure, coronary artery disease, and/or poor ability to heal may find few surgeons willing to operate. Nonetheless, there are ways of getting patients safely through an operation if they decide that the benefits in terms of quality of life and daily activities are worth the risk. In cases of complex regional pain syndrome or phantom pain, surgery may not provide relief or may exacerbate symptoms.

The next step is to evaluate the patient's ability to heal from the surgical incision. Accepted methods of assessment are transcutaneous oxygen measurement (TcOM), as well as standard non-invasive vascular studies. The patient's general health, age, comoribidities, nutrition, tobacco use, and glucose management help to develop a profile of healing potential.

Case 2 (described on pg. A-10): Before revision surgery (top). Preoperative x-rays revealed multiple exostosis, also in the area of pain described by the patient and confirmed by pain on palpation (left). Large sciatic neuroma heavily invested in the exostosis (right).

Patients' Needs and Goals

Surgery can range from finding and removing neuromas to complex repairs and reconstruction. Some patients may only want minimal surgery despite the benefits of a more extensive revision. Many factors go into a patient's decision:

- Current level of pain, impaired function, and/or recurrent problems.
- Anticipated recovery time, including time away from work.
- Expected degree of improvement.
- Risks and pain associated with surgery.
- Availability of an experienced surgeon.
- Past history, including the circumstances surrounding their primary amputation(s).
- Insurance coverage.

A thorough, informed consent helps patients to make decisions they are comfortable with so that their expectations are consistent with the projected surgical outcome.

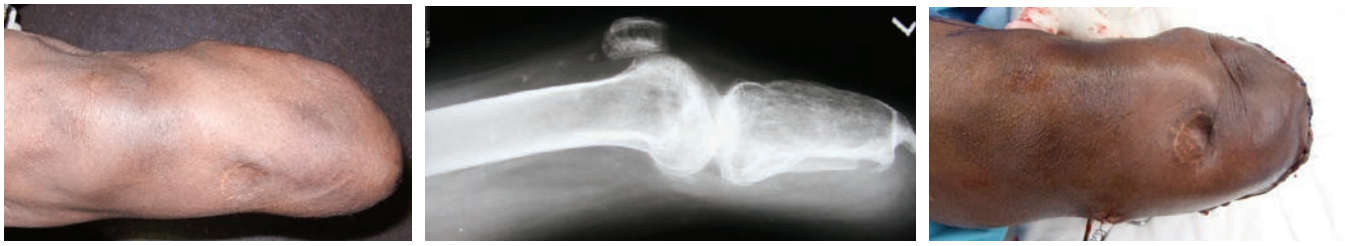

Case 3 (described below): Before revision surgery (left). Extosis of tibia (middle). Post revision surgery (right).

Case Histories

Case 1: Revision for Soft Tissue Problem

A 56-year-old female with a transfemoral amputation secondary to a motor vehicle accident (MVA). This patient had a prior osteomyoplastic reconstruction, yet she still had difficulty with prosthetic fit. She also experienced skin irritation. The initial exam did not reveal a significant issue until the patient stood, and there was an obvious redundancy. The patient reported a wrapping sensation in her socket. Surgery was performed to remove excess soft tissue (1.2 lb.) and an inclusion cyst that had developed (see images on pg. A-8).

Case 2: Revision for Pain

A 30-year-old male with an above-knee amputation secondary to trauma with a nine-month history of poor prosthetic fit and weight gain secondary to increased inactivity. The patient has redundant soft tissue and also complained of exquisite posterior pain. Surgical revision included a resection of exostosis, sciatic neuroma, and soft tissue excision, with osteomyoplastic reconstruction. The clinical exam revealed a suspected sciatic neuroma, which was confirmed by pathologic specimen. This neuroma was not visible on multiple MRIs (see images on pg. A-9).

Case 3: Revision for Overgrowth of the Tibia

A 50-year-old female patient who had her left leg amputated secondary to a pedestrian motor vehicle collision more than 20 years ago. Following the amputation, this patient had a good return to function, but her ability to stand continuously diminished over the years from 4–6 hours per day to 2–3 hours per day. An exam revealed tenderness at the extreme tip of her residual limb, and efforts to off-load using a patellar-tendon-bearing (PTB) socket helped only for 9–12 months.

Her clinical exam demonstrated marked atrophy of her residual limb musculature.

Pre-operative evaluation included plain x-rays, which revealed a rather prominent, buck-toothed shaped exostosis as the source of her pain and inability to weight bear.

Osteomyoplastic revision with resection of the exostosis was performed with a subsequent return to function and continued employment (see images above).

Case 4: Deep Ulcer Treated without Surgery

A 50-year-old female with diabetes mellitus, who was noted by caregivers to be avoiding prosthetic wear. Despite having been ambulatory, this patient remained continuously in a wheelchair.

Case 4 (described above): Deep ulcer treated without surgery.

She had not seen a prosthetist in two years. She was sent to a wound center for "ulcer" evaluation and treatment. She presented with a deep, full-thickness ulcer affecting the medial epicondyle as shown. Her prosthetic liner demonstrated a large hole in the same area. Off-loading for three weeks and appropriate dressings healed the wound without surgery (see image above).

References

1. Sheffield PJ, Fife CE, eds. *Wound Care Practice.* 2nd ed. Flagstaff, AZ: Best Publishing Company; 2007.
2. Carroll K, Edelstein, J. *Prosthetics and Patient Management: A Comprehensive Clinical Approach.* Thorofare, NJ: SLACK Incorporated; 2006.
3. Sussman C, Bates-Jensen B. *Wound Care: A Collaborative Practice Manual for Health Professionals.* 3rd ed. Baltimore, MD: Lippincott Williams & Wilkins; 2006.

Treating Skin Conditions of the Amputee

■ Clay Kelly, MD

The environment inside a prosthetic socket is inhospitable to normal skin. Conditions such as moisture, heat, pressure, and shear place stress on the skin and create a hospitable environment for bacteria. Kelly M. Bui, MD, et al. described the prevalence of skin problems among amputees as between 15 and 41 percent, with the most commonly reported skin problems being wounds, abscesses, and blisters. When these problems occur, common underlying causes of amputation such as diabetes and vascular disease may impair the skin's ability to maintain itself or heal. When this is coupled with patients' needs to carry on with their daily activities, skin may not be able to recover. The goal of this article is to describe the most common skin issues faced by prosthetic users and appropriate treatment options.

Figure 1: Acute verrucous hyperplasia. This residual limb was quite malodorous, which was out of character for this patient.

The interdisciplinary team approach is the best way to manage skin problems, with the physician, prosthetist, and physical therapist attending the amputee clinic. These key team members evaluate the amputee's skin to determine the cause of the skin problem. They can then agree on a treatment plan that typically includes dressings, topical or oral medication, prosthetic modifications, and a wearing schedule. Ideally, the patient may return home from this visit with a prescription and therapy instructions in hand, as well as prosthetic modifications initiated or completed. When services are not provided in the same location, communication is key. Photographs and telemedicine may enhance separate site co-management, but care must be taken to ensure the patient's privacy.

Prosthetic fit, material selection, and rest are typically the keys to resolving abnormal skin conditions. Problems arise when patients do not respond quickly enough to changes in their residual limbs with appropriate volume management, hygiene, and required visits for prosthetic adjustments. If skin conditions persist or become severe, patients should be referred to a physician.

Figure 2: Verrucous hyperplasia three weeks later. Patient was treated with topical antibiotics, followed by topical steroids. The socket had immediately been adjusted to total contact.

The Prosthetic Socket Environment

Contact dermatitis and allergic dermatitis refer to skin irritations due to exposing the skin to noxious substances. A mild reaction may include local redness, swelling, and itchiness. Blister formation and skin "weeping" are more severe reactions. Topical steroids and removal of the irritating or allergic agent is the treatment. This typically means changing liners or suspension sleeves. If the response to a new material is uncertain, a small piece of the material can be placed against the patient's skin for a few days to judge the reaction. It is reasonable for the prosthetist to try different materials and look for resolution to this breakout. Referral of these cases to the amputee's physician or an amputee rehabilitation specialist is recommended. A dermatologist may be needed for allergy testing.

In new amputees, occasionally the residual limb will become globally reddened and swollen after the initial wearing of the prosthesis. This is typically a condition known as reactive hyperemia and will improve as the residual limb becomes accustomed to this new stressor. A typical wearing schedule for a new amputee is to wear the prosthesis for one to two hours, then remove the leg and check the skin. If the patient is working with a physical therapist, this professional may oversee an increase in wearing times. Patients should check their skin each time the prosthesis is removed. A handheld mirror may help those with limited range of motion.

Skin or scar tissue that adheres to tendon and bone may lead to irritation from shear forces during prosthetic wear and ambulation. The physical therapist may perform deep-tissue massage and instruct the amputee on this process. If it becomes a recurrent area of breakdown despite socket modifications, the patient should be referred to his or her surgeon for revision.

Verrucous hyperplasia is rarely seen since almost all present-day sockets are designed with total contact fitting. It may still occur if residual limb changes lead to proximal constriction, distal space, and excessive moisture in the socket environment. Figures 1 and 2 show an excellent outcome from adjusting to a total contact socket, which is the key in treatment.

Figure 3: Anterior skin thickening on a transtibial amputee.

Sweating: Current suction and gel-liner fitting methods have led to skin problems associated with moist environments. This is not as much of an issue in patients who fit with socks directly against the skin, as the socks absorb moisture and can be changed midday to alleviate any moisture-related skin issues. There are three main approaches to manage sweating within the socket.

1. A "wet"' fit using a zinc-based cream. This approach may become considered risky from the medical perspective as zinc toxicity is becoming a recognized clinical entity.
2. Topicals such as talc to help absorb moisture. This may, however, make the environment more hospitable to fungal infection.
3. Antiperspirant, aluminum chloride hydroxide, applied on the skin prior to donning the socket. This is an effective remedy; however, repeated or prolonged exposure can lead to skin irritation. Given the enclosed environment of the socket, patients should be instructed to watch their skin and discontinue use if irritation occurs.

Excessive in-socket moisture can lead to **maceration** of the skin. This is a loosening of the keratin layer of the skin, which can slough when exposed to pressure or shear. This condition produces burning and a locally irritated area of skin.

Miliaria is the most common problem in the residual limb as a result of sweating. It is a disorder of the eccrine sweat glands known to occur in increased heat and humidity. Blockage of the sweat ducts leading to leakage of sweat into the skin around the sweat ducts is thought to be the mechanism. Occlusion with a warm, moist environment have been shown to be causative factors. Treatment includes cooling the skin and trying to maintain a less moist environment. A socket-wearing schedule may be necessary, and topical steroids may be required in refractory cases. If this condition worsens or becomes uncomfortable, a visit to the physician is warranted.

Botulinum toxin (Botox®) has been used for excessive sweating in the axillary area (armpit) and the palms. Anecdotal cases have been treated for residual limb sweating; this writer has treated four cases. It is a rather tedious procedure involving between 40 and 60 subcutaneous injections (forming a wheal) at one- to two-inch intervals on the residual limb. Efficacy has been good, but the effect may last as short as four months, and the Botox effect has been shown to decrease with repeated administrations. High cost is also an issue for these procedures.

Figure 4: Distal blisters on a transtibial amputee. The large one has some bleeding into it.

Figure 5: An epidermal cyst is visible on the medial part of this residual limb.

Closed Skin Problems

The most common skin change from wearing the socket is **skin thickening** (Figure 3) at surfaces subject to repetitive pressure loading. In the transtibial amputation, this may be distal, distal anterior, infrapatellar, and, less likely, at the fibular head and medial tibial flare. Skin thickening is simply the compression of the outer layer of the skin (stratum corneum) such that it is not so easily sloughed off. It is commonly seen on the soles of the feet, where consistent weight bearing is done. This may be considered adaptive or protective, allowing the skin to stand up to the rigors of prosthesis usage.

When skin is exposed to rubbing, or shear, **blisters** (Figure 4) may develop. This is separation of the skin, or epidermis, from its base. Typically this fills with fluid (serum). It is unusual for this problem not to be heralded by localized pain complaints such as burning. It should be noted that blisters that become larger than one-half inch across are referred to as bullae. The most common areas in the transtibial prosthesis are distal, distal anterior, infrapatellar, and hamstring tendons; the medial tibial flare and fibular head may also be prone to pressure if they are prominent. In the transfemoral amputee, distal, distal anterior, distal posterior, ischial, and groin are the susceptible areas. These are essentially grade two ulcers that remain covered and which may transform into a blood blister. A blister should be left as is, not "popped." Aside from local pressure relief, there is no application for a closed blister. Blisters may spontaneously rupture and then need to be treated as an open wound. If they do not rupture, they will still require some time to heal, but the risk of infection is lower. Referral to the physician is advised for blisters that grow in size, will not resolve, or become open wounds.

Figure 6: Grade 2 ulcer on a transtibial amputee.

An epidermal (sebaceous) cyst (Figure 5) is a small cystic lesion found on the residual limb. It is lined with keratin, forming a whitish protruding mass. It is usually not inflamed and often is referred to as a "skin pearl." Most patients complain that local pain is the main problem. Since epidermal cysts are not large or protruding, local socket relief is the main prosthetic intervention. Small cysts can be removed by local dissection with a hypodermic needle; larger and recurrent cysts require surgical excision.

Ulcers: When the skin becomes reddened and irritated by pressure or shear or opens, this is a pressure ulcer. The pressure ulcer grading system is useful here although not specifically designed for amputees:

- **Grade one:** Unblanchable erythema due to pressure shear.
- **Grade two:** Extends through the epidermis and dermis.
- **Grade three:** Opens into the fascia.
- **Grade four:** Opens to bone, ligament, or tendon.

Treatment of these ulcers depends upon their condition. Grade one ulcers do not need dressing but do need relief of the pressure. Unfortunately, it is often the instinct of the patient to put a bandage or other cushion over these areas since they typically are associated with pain. Given the intimate nature of prosthetic fit, this is likely to increase the pressure or aggravate the shear, worsening the problem. The key, as it is with most skin conditions, is prosthetic relief or modification to improve socket fit and alignment. Grade two through four ulcers are best treated with physician collaboration.

The grade two ulcer (Figure 6) does require some sort of dressing, and an ulcer of this severity is often treated while

Figure 7: Folliculitis. *Source http://atlasdermatologico.com.br/*

Figure 8: Cellulitis on a transtibial limb with distal invagination.

allowing patients to continue wearing their prosthesis. As long as there is not associated infection or wound eschar (scab), these wounds are well suited to treatment with hydrocolloid dressings (DuoDERM®, Tegaderm™, Restore), which protect the wound, relieve shear and some pressure, and provide a moist, clean healing environment. They can be applied and left on for 48 hours; then they should be changed and the wound should be inspected. Some liquification around the wound on the inside of the dressing is typical.

Grade three and four wounds are deeper and imply a more acute insult or neglected problems with prosthetic fit. The risk for deep-tissue infection here is greater, and it is uncommon to manage these cases without discontinuing prosthetic use. These patients must come under the care of a physician so they can be evaluated for deep-tissue infection and appropriate topical treatments and dressings can be applied. Often there is local edema, and prosthetic wearing is interrupted. Adjustments may need to be postponed until the wound has improved enough to utilize the limb again. Low-compression shrinkers such as Compressogrip™ may be used to help maintain residual limb shape in these cases. They may also help to secure the dressing to the wound. The physician is likely to see the patient one week after the first visit to assure improvement and then advise the prosthetist when it is appropriate for the patient to resume using the prosthesis.

Infection

Bacteria are ever present on the human skin, and the enclosed, moist conditions of the socket may allow an environment in which they thrive. Hygiene is a major issue with suction liner sockets. There are several conditions of the residual limb in which bacteria play a major role.

Folliculitis (Figure 7) is occlusion, bacterial proliferation (local infection), and pus formation inside the hair follicle. It differs from miliaria in that it is specifically located in the hair follicle. This condition is essentially like acne. Treatment is primarily good hygiene and local topicals such as benzoyl peroxide and salicylic acid. When folliculitis increases in size and extends outside of the follicle, it is referred to as a furuncle (boil). If these subsequently begin to coalesce between follicles, the condition becomes a carbuncle. Carbuncles can be harder to treat, since pockets of infection may persist (loculation). Treatment is drainage, light wound packing, and oral antibiotics. Decisions about socket usage are made on a case-by-case basis.

Cellulitis is a skin infection (Figure 8) characterized by erythema (redness), warmth, and swelling. It may develop in breaks in the skin and in closed-in situations, like a socket. Mild local cases can sometimes be handled with topical antibiotics, but typically a ten-day course of oral antibiotics that cover staphylococcus or streptococcus is given. The key to prevention is good prosthetic and residual-limb hygiene.

Figure 9: Patchy fungal infection (tinea stumpis).

Figure 10: Classic "ringworm" fungal infection.

Fungal infection (tinea stumpis) of the residual limb is common. Again, it is the moist, occluded environment that allows the fungus, present on all of us, to propagate. Presentation may be patchy, "angry" redness with small satellite lesions (Figure 9), or classic ringworm (Figure 10). This is easily treated with topical antifungals and, of course, good hygiene is the key to prevention.

Hygiene can prevent or resolve many of the skin conditions mentioned above. For the skin, this includes daily washing with moisturizing soap and patting dry. Prosthetic socks should be washed daily and rotated (much like regular socks). Suction liners should be wiped down daily with soap and water, rinsed well with water, and thoroughly dried. Rotating two liners is advisable. At least once weekly, a wipe down with isopropyl alcohol should be done, which will help decrease the bacterial load.

References

1. Bui KM, Raugi GJ,Nguyen VQ, Reiber GE. Skin problems in individuals with lower-limb loss: Literature review and proposed classification system. *J Rehabil Res Dev.* 2009;46(9):1085–1090.
2. Kelly CM. Skin Disorders and Their Management. In In Carroll K, Edelstein JE, eds. *Prosthetics and Patient Management—A Comprehensive Clinical Approach.* Thorofare, NJ: SLACK Incorported; 2006.
3. Levy SW, *Skin Problems of the Amputee*. St. Louis, MO: Warren Green Incorporated; 1983.
4. Lionelli GT. Wound dressings. *Surg Clin of North Ame.* 2003;83(3):617–638.
5. Lyon CC, Kulkarni J, Zimerson E, Van Ross E, Beck MH. Skin Disorders in Amputee. *J of the Am Acad of Dermatol.* 2000;42(3):501–507.

The Academy Grant
A Plan for Continuing Initiatives

As the Academy leadership and volunteers planned the initiatives and activities to undertake with funding from the Department of Education, it was always with the knowledge that these funds might not be available in the future. At this time we do not yet know whether or not we will receive any additional funding from the Department of Education for the 2011 fiscal year. But since planning for sustainability of our initiatives has always been a key focus of our efforts, the work continues.

O&P Awareness

The Academy is continuing its efforts to make the public aware of the unique career opportunities available in O&P. We will distribute our award-winning O&P career awareness kits to individuals interested in learning more about the profession and to residents and practitioners who wish to use them as handouts as they conduct career awareness training sessions at local high schools and in other venues.

As a direct result of the Academy grant's "Great Barriers Meeting," the Academy began publishing periodic literature updates.... These literature updates include both article abstracts and full-text articles and are sent to all Academy members.

We will hold a high school awareness event at this year's Annual Meeting and Scientific Symposium (March 16–19) in Orlando, Florida, where local students have been invited to a session in which they can learn about the profession through presentations, hands-on demonstrations, and a tour of the Exhibit Hall. Current O&P students who work with us on this program will be eligible for reduced registration at the meeting.

Access to Research

As a direct result of the Academy grant's "Great Barriers Meeting," the Academy began publishing periodic literature updates. These updates are intended to raise members' awareness of research being published in journals beyond those focused exclusively on O&P. These literature updates include both article abstracts and full-text articles and are sent to all Academy members.

In addition, the Academy has established a committee to begin work on producing a series of Critically Appraised Topics (CATs). CATs are designed to address clinically derived and clinically relevant questions. Each CAT will address a single clinically encountered question, be based on only the most recent and relevant literature, and be no more than two pages in length. These unique secondary knowledge sources will be available to all Academy members.

The Academy will also publish the Evidence Notes produced during the last year of the grant in upcoming issues of *The Academy TODAY.* These are summaries of more extensive literature reviews that were conducted on "The Effect of Ankle-Foot Orthoses on Balance," "Outcomes Associated with the Use of Microprocessor and Non-Microprocessor Controlled Prosthetic Knees after Unilateral Transfemoral Limb Loss," and "Residual Limb Volume Change."

State-of-the-Science Conference

During the past year of the grant we were able to conduct an additional State-of-the-Science Conference (SSC) that was not originally part of our plan. The Proceedings of the SSC on "The Effect of Ankle-Foot Orthoses (AFOs) on Balance" were published and mailed with the October 2010 issue of the *Journal of Prosthetics and Orthotics (JPO)* and are available on the Academy's website at www.oandp.org. In addition, the Academy hopes to work with one of our NCOPE-accredited O&P schools to develop this SSC into an online course that would also be posted to the Academy's Paul E. Leimkuehler Online Learning Center (OLC).

Looking Ahead

As we look to the future, we are hopeful that we will be able to secure additional federal funding to continue the important work that our past grant funds have enabled us to undertake. But we are confident that the effort made to create sustainable programs will enable us to continue to move the field forward.

For more information about these programs or any of the Academy's grant-related or other activities, contact Kimber Nation, grant administrator and council coordinator, at knation@oandp.org or call 202.380.3663.

EZ Flex Liner

Alps New EZ Flex Liner (anterior view shown above) is available in 3mm or 6mm Uniform thicknesses. Eight sizes fit circumferences of 16 cm to 44 cm.

Medial view of the knee in flexion demonstrates the greater elasticity of the anterior fabric to extend over the front of the knee. Paring it with the limited vertical stretch posterior fabric reduces the overall effort expended by the amputee to bend the knee and increases comfort.

NOW IN STOCK:

Cascade PEL SPS

© 2010 ALPS. All Rights Reserved.

Practical Magic

Hardly just a pretty face,the EZ Flex Liner delivers unequaled function without sacrificing anything.

Unified Flexible Front

The unique fabric on the anterior surface provides unlimited stretch over the patella for greater elasticity while reducing pressure on the knee and the amount of energy required to flex the knee

80% Less Vertical Stretch Posteriorly

As compared to other Alps gel liners, virtually eliminating pistoning while minimizing bunching behind the knee during flexion

Antioxidants & EZ Gel Protect Skin--

Antioxidants in EZ Gel help protect the skin from damage caused by free radicals.

ALPS EZGel is perfect for those with poor skin characteristics or sensitive tissues.

Budget Friendly--

No other liner on the market provides this quality, durability and functionality at this price... absolutely no other!

ALPS

800.574.5426
www.easyliner.com
info@easyliner.com