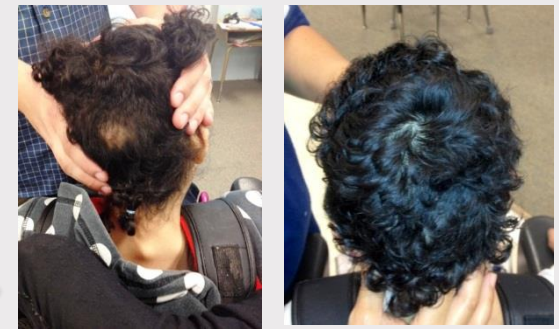
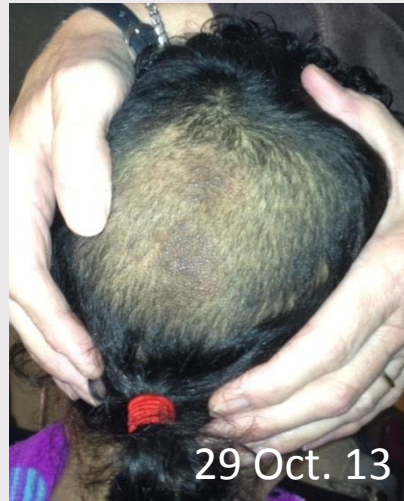
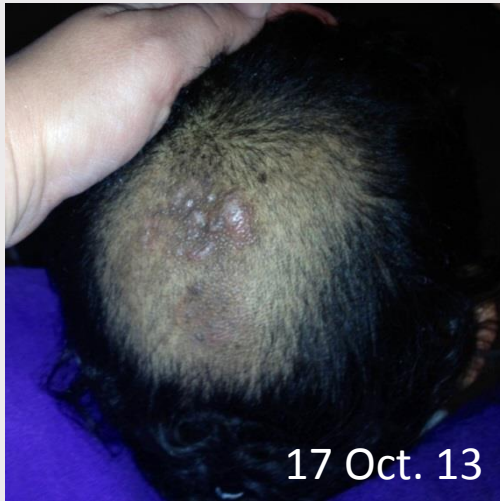

17-Oct-13

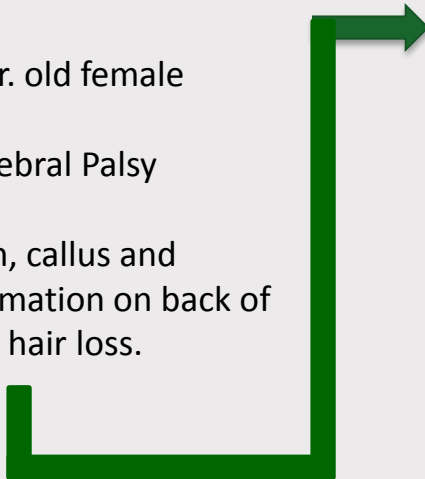
Patient: 14 yr. old female

Diagnosis:

Athetoid Cerebral Palsy

Condition:

Inflammation, callus and blistering formation on back of head. Severe hair loss.



23-Oct-13

GlideWear® application at wheelchair head support bed-cover and pillowcase



29-Oct-13

Inflammation and blistering resolved. Hair is growing again (**GlideWear in use for 6 days**)

Long term result 2014

2014

Student still using the GlideWear-covered headrest. Small spot with reduced hair growth remaining (10-Jun-14).
Hair problem resolved (25-Aug-14).